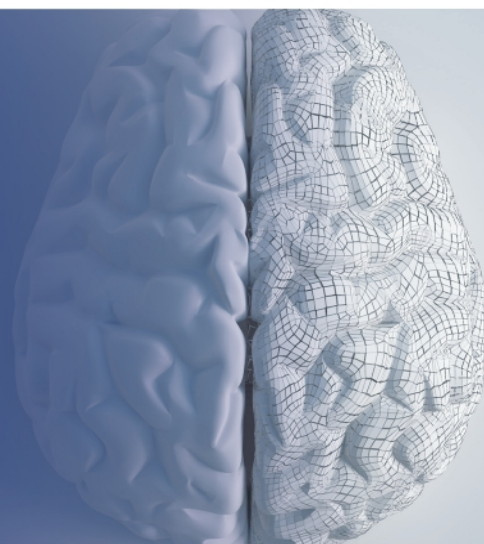

Epilepsy Knowledge Hub

Access the latest ILAE Guidelines
webinars on demand



The Epilepsy Knowledge Hub is intended to provide health care professionals with the latest research and tools to aid in the diagnosis, classification, and subsequent treatment for patients with epilepsy syndromes at various ages.

This resource has been created in coordination with Epilepsia, a peer-reviewed journal published by Wiley on behalf of the International League Against Epilepsy (ILAE). Previous webinars are available on-demand on this site for CME credits.

[Visit now](#)

Access the hub for free access to:



Videos



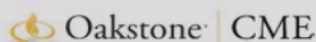
Infographics



Articles

[Access now](#)

This educational resource has been supported by Zogenix International Limited, now a part of UCB. Zogenix International Limited has had no influence over the content or selection of the Editorial Panel.

























Jointly Provided by Oakstone Publishing and John Wiley and Sons Limited

This activity was planned and implemented in accordance with the accreditation requirements and policies of the Accreditation Council for Continuing Medical Education (ACCME) through the joint providership of Oakstone Publishing and John Wiley and Sons Limited, Oakstone Publishing is accredited by the ACCME to provide continuing medical education for physicians.

Oakstone Publishing designates this recording activity for a maximum of 1.0 AMA PRA Category 1 Credits™. Physicians should claim only the credit commensurate with the extent of their participation in the activity.

SPECIAL REPORT

The ILAE consensus classification of focal cortical dysplasia: An update proposed by an ad hoc task force of the ILAE diagnostic methods commission

Imad Najm¹  | Dennis Lal^{1,2,‡}  | Mario Alonso Vanegas^{3,‡}  |
 Fernando Cendes^{4,5,†}  | Iscia Lopes-Cendes^{4,6,‡}  | Andre Palmini^{7,8,†}  |
 Eliseu Paglioli^{9,‡} | Harvey B. Sarnat^{10,†} | Christopher A. Walsh^{11,12,†}  |
 Samuel Wiebe^{13,‡}  | Eleonora Aronica^{14,15,†}  | Stéphanie Baulac^{16,‡}  |
 Roland Coras^{17,‡} | Katja Kobow^{18,‡}  | J. Helen Cross^{18,†}  | Rita Garbelli^{19,†}  |
 Hans Holthausen^{20,‡}  | Karl Rössler^{21,‡} | Maria Thom^{22,†}  | Assam El-Osta^{23,‡}  |
 Jeong Ho Lee^{24,†}  | Hajime Miyata^{25,†}  | Renzo Guerrini^{26,‡}  |
 Yue-Shan Piao^{27,‡}  | Dong Zhou^{28,‡}  | Ingmar Blümcke^{1,17,†} 

¹Charles Shor Epilepsy Center, Neurological Institute, Cleveland, Ohio, USA

²Genomic Medicine Institute, Cleveland Clinic, Cleveland, Ohio, USA

³International Center for Epilepsy Surgery, Hospital HMG, México City, Mexico

⁴Brazilian Institute of Neuroscience and Neurotechnology (BRAINN), University of Campinas – UNICAMP, Campinas, Sao Paulo, Brazil

⁵Department of Neurology, University of Campinas – UNICAMP, Campinas, Sao Paulo, Brazil

⁶Department of Translational Medicine, University of Campinas – UNICAMP, Campinas, Sao Paulo, Brazil

⁷Department of Clinical Neurosciences, School of Medicine, Pontificia Universidade Católica do Rio Grande do Sul (PUCRS), Porto Alegre, Brazil

⁸Porto Alegre Epilepsy Surgery Program, Hospital São Lucas PUCRS, Porto Alegre, Brazil

⁹Department of Surgery, School of Medicine, Pontificia Universidade Católica do Rio Grande do Sul (PUCRS), Porto Alegre, Brazil

¹⁰Department of Paediatrics, Department of Pathology (Neuropathology) and Department of Clinical Neurosciences, University of Calgary Faculty of Medicine, Alberta Children's Hospital Research Institute, Calgary, Alberta, Canada

¹¹Division of Genetics and Genomics and Howard Hughes Medical Institute, Department of Pediatrics, Boston Children's Hospital, Boston, Massachusetts, USA

¹²Departments of Pediatrics and Neurology, Harvard Medical School, Boston, Massachusetts, USA

¹³Department of Clinical Neurosciences, Cumming School of Medicine, University of Calgary, Calgary, Alberta, Canada

¹⁴Department of (Neuro) Pathology, Amsterdam UMC, University of Amsterdam, Amsterdam, The Netherlands

¹⁵Stichting Epilepsie Instellingen Nederland (SEIN), Heemstede, the Netherlands

¹⁶Sorbonne Université, Institut du Cerveau - Paris Brain Institute - ICM, Inserm, CNRS, APHP, Hôpital de la Pitié Salpêtrière, Paris, France

¹⁷Department of Neuropathology, Universitätsklinikum Erlangen, Erlangen, Germany

¹⁸Developmental Neurosciences Programme, UCL NIHR BRC Great Ormond Street Institute of Child Health and Great Ormond Street Hospital for Children NHS Foundation Trust, London, UK

¹⁹Epilepsy Unit, Fondazione IRCCS Istituto Neurologico Carlo Besta, Milan, Italy

²⁰Center for Pediatric Neurology, Neurorehabilitation and Epileptology, Schoen-Clinic, Vogtareuth, Germany

[†]Member of the ILAE Task Force on Focal Cortical Dysplasia (# chair).

[‡]Invited consulting expert.

This is an open access article under the terms of the [Creative Commons Attribution-NonCommercial](https://creativecommons.org/licenses/by-nc/4.0/) License, which permits use, distribution and reproduction in any medium, provided the original work is properly cited and is not used for commercial purposes.

© 2022 The Authors. *Epilepsia* published by Wiley Periodicals LLC on behalf of International League Against Epilepsy.

²¹Department of Neurosurgery, Allgemeines Krankenhaus Wien, Vienna Medical University, Wien, Austria

²²Department of Neuropathology, Institute of Neurology, University College London, UK

²³Epigenetics in Human Health and Disease Laboratory, Central Clinical School, Monash University, Melbourne, Victoria, Australia

²⁴Graduate School of Medical Science and Engineering, KAIST and SoVarGen, Daejeon, South Korea

²⁵Department of Neuropathology, Research Institute for Brain and Blood Vessels, Akita Cerebrospinal and Cardiovascular Center, Akita, Japan

²⁶Neuroscience Department, Children's Hospital Anna Meyer- University of Florence, Florence, Italy

²⁷National Center for Neurological Disorders, Department of Pathology, Xuanwu Hospital, Capital Medical University, and Clinical Research Center for Epilepsy, Capital Medical University, Beijing, China

²⁸Department of Neurology, West China Hospital, Sichuan University, Chengdu, China

Correspondence

Imad Najm, Charles Shor Epilepsy Center, Cleveland Clinic, 9500 Euclid Avenue, Cleveland, OH 44195 USA.
Email: najmi@ccf.org

Abstract

Ongoing challenges in diagnosing focal cortical dysplasia (FCD) mandate continuous research and consensus agreement to improve disease definition and classification. An International League Against Epilepsy (ILAE) Task Force (TF) reviewed the FCD classification of 2011 to identify existing gaps and provide a timely update. The following methodology was applied to achieve this goal: a survey of published literature indexed with ((Focal Cortical Dysplasia) AND (epilepsy)) between 01/01/2012 and 06/30/2021 ($n = 1349$) in PubMed identified the knowledge gained since 2012 and new developments in the field. An online survey consulted the ILAE community about the current use of the FCD classification scheme with 367 people answering. The TF performed an iterative clinico-pathological and genetic agreement study to objectively measure the diagnostic gap in blood/brain samples from 22 patients suspicious for FCD and submitted to epilepsy surgery. The literature confirmed new molecular-genetic characterizations involving the mechanistic Target Of Rapamycin (mTOR) pathway in FCD type II (FCDII), and *SLC35A2* in mild malformations of cortical development (mMCDs) with oligodendroglial hyperplasia (MOGHE). The electro-clinical-imaging phenotypes and surgical outcomes were better defined and validated for FCDII. Little new information was acquired on clinical, histopathological, or genetic characteristics of FCD type I (FCDI) and FCD type III (FCDIII). The survey identified mMCDs, FCDI, and genetic characterization as fields for improvement in an updated classification. Our iterative clinico-pathological and genetic agreement study confirmed the importance of immunohistochemical staining, neuroimaging, and genetic tests to improve the diagnostic yield. The TF proposes to include mMCDs, MOGHE, and “no definite FCD on histopathology” as new categories in the updated FCD classification. The histopathological classification can be further augmented by advanced neuroimaging and genetic studies to comprehensively diagnose FCD subtypes; these different levels should then be integrated into a multi-layered diagnostic scheme. This update may help to foster multidisciplinary efforts toward a better understanding of FCD and the development of novel targeted treatment options.

KEYWORDS

brain, classification, epilepsy, focal cortical dysplasia, genes, seizure

1 | INTRODUCTION

In 1957, Crome first described a different form of “ul-egyria” with largely irregular “nerve cells and stout tortuous processes.”¹ In 1971, David Taylor coined the term “focal cortical dysplasia” based on irregular dysmorphic neurons and enlarged ballooned cells in the setting of microscopically discernable architectural disorganization of the neocortex in patients with focal epilepsies.² Since then, focal cortical dysplasia (FCD) has been associated with medically intractable epilepsy³ that carries a less favorable prognosis for a seizure-free outcome following surgical resection than hippocampal sclerosis and developmental brain tumors.^{4,5} However, imaging techniques have enabled the presurgical detection and increased awareness of the incidence and importance of FCD as a common pathological cause of medically intractable epilepsy.⁶

These electro-clinical observations led to multiple attempts to classify FCD^{7,8} with pathological subdivisions that correlate with relevant clinical, electroencephalographic, and imaging features and directly affect management of epilepsies associated with FCD and their postsurgical outcomes. From a histopathological standpoint, a category of frequently encountered architectural abnormalities of the neocortex but no cytopathology features was introduced⁷ and later assigned to FCDI in the Palmini classification.⁸ In addition, the Palmini classification made the first attempt toward a clinico-pathological correlation and formally classified FCD into two subtypes—FCDI and FCDII—and two additional subtypes for each one of these groups. Subsequent studies showed that the microscopic hallmarks for a reliable and consistent histopathological diagnosis of FCDI remained poor.⁹ These challenges were addressed in the first international FCD consensus classification of 2011.¹⁰ The International League Against Epilepsy (ILAE) classification expanded Palmini type I into three subtypes with reference to architectural abnormalities and lack of any other principal lesion (**Figure 1B and C**). ILAE type II and Palmini type II subtypes remained identical. However, FCDIII and its four subtypes were newly introduced and defined as the presence of architectural abnormalities in association with another “principal” lesion: hippocampal sclerosis (FCDIIa, **Figure 1E**), low-grade developmental brain tumors (FCDIIb), vascular malformations (FCDIIc, **Figure 1F**), or any other lesion acquired during early life (FCDIIId, **Figure 1G and H**).

Key Points

- An International League Against Epilepsy (ILAE) Task Force (TF) reviewed the ILAE classification of focal cortical dysplasia (FCD) from 2011 to identify existing challenges and gaps in the clinical and histopathological diagnosis of FCD
- A review of published literature since the release of the FCD classification in 2011 identified a substantial gain of knowledge in the electro-clinical-imaging phenotyping and genetic characterization of FCD
- An international agreement study of histopathology and genetic analysis confirmed the importance of immunohistochemical staining and the phenotype-genotype integration
- An update of the 2011 FCD classification scheme is proposed with the addition of mild malformations of cortical development (mMCDs), (mMCDs) with oligodendroglial hyperplasia (MOGHE), and “no definite FCD on histopathology” as new categories
- The TF also proposes a multi-layered diagnostic scheme integrating histopathology with imaging data and genetic findings

2 | MATERIALS AND METHODS

2.1 | Meetings of the task force on FCD and manuscript generation

During its term (2017–2021), the Task Force (TF) met in person at the annual American Epilepsy Society meetings in Washington, D.C. (2017), New Orleans (2018), and Baltimore (2019); at the International Epilepsy Congress in Bangkok, Thailand in 2019; and during the Cleveland Clinic FCD Summit in 2019. In addition, the TF met online in December 2020. The discussions during the meetings included: (1) a review of the current state of knowledge since the first ILAE classification was published in 2011^{11,12}; (2) design, execution, and analyses of the findings of an expert survey of the current use and challenges of the FCD classification; and (3) a discussion of the results of an iterative histopathological agreement and genetic study.¹³ The summary of the literature review, the results of the survey and the agreement study, and the recommendations for a first

update of the ILAE classification were written initially in this manuscript by two members of the TF (IN and IB). The second version was reviewed by the other members of the TF, and the third version was later discussed with consulting experts who were selected by the TF to equally represent specialists across disciplines and geographical destinations. The final version of the manuscript was reviewed and approved by all the authors of the update.

2.2 | New knowledge established since the 2011 classification

The published English literature indexed in PubMed between 01/01/2012 and 06/30/2021 (using the terms “Focal cortical dysplasia” and “Epilepsy”) was surveyed. New clinical, electroencephalographic, imaging, and genetic data were identified in the pool of 1349 scientific publications. Some of the new knowledge was judged by members of the TF as potentially impacting the clinical diagnosis and management of FCD, and future research on these malformations.^{11–13}

2.3 | The 2018 online survey of the ILAE task force

An online survey was performed in 2018 to consult the ILAE community about the current use and challenges of the FCD classification scheme of 2011 (see details in the Appendix S1). The survey was advertised on the ILAE website in addition to the ILAE newsletter. It was freely accessible for 6 weeks via the ILAE website. Questions in the survey focused on the following: (1) The use of the 2011 classification (Yes/No), (2) the % of FCDI and FCDII in the respondent practice, (3) the % of various FCDI subtypes in the respondent practice, (4) the use of genetic testing in the blood and brain samples of patients with suspected FCD, (5) the use of FCDIII subtype (Yes/No), (6) the prevalence of each principal lesion associated with FCDIII in the respondent practice, (7) the use of mild malformations of cortical development (mMCDs) (Yes/No), (8) in comparison to FCD, how often mMCD was used (less/same/more), (9) the aspect(s) of the FCD classification that needs revision (FCDI, FCDII, FCDIII, mMCD, Genetics). Questions 10–14 were addressed to neuropathologists: (10) use of immunohistochemistry (IHC) in the diagnosis of FCD (for neuropathologists only), (11) use of IHC in the diagnosis of brain tumors, (12) their knowledge about the ILAE recommendation for histopathology workup (Yes/No), (13) their use of the ILAE recommendations for histopathology workup

(Yes/No), (14) do they archive frozen tissue (Yes/No)? Two more questions were on (15) the geographical location and (16) specialty of the respondent.

2.4 | The iterative histopathology agreement study

As recently reported, the TF initiated an iterative histopathological agreement trial completed by 20 neuropathologists (of 38 invited) from 16 countries using a consecutive series of 196 surgical tissue blocks obtained from 22 patients with epilepsy at a single center.¹³ In addition, five independent genetic labs performed screening or validation sequencing of FCD relevant genes, that is, the FCD gene panel, in paired brain and blood samples from the same patients. All study results were discussed comprehensively and published in a peer-reviewed journal.¹³

3 | RESULTS

3.1 | New knowledge and challenges in the first ILAE classification

The new knowledge includes the characterization of new diagnostic entities,¹⁴ either by anatomic-clinico-pathological studies in FCDII located at the bottom of sulcus^{15,16} or a persistent genotype–phenotype pattern in mMCD with oligodendroglial hyperplasia and epilepsy (MOGHE) with *SLC35A2* brain mosaicism.¹⁷ In addition, new knowledge gathered in the neurophysiology of FCD, advanced neuroimaging findings, postsurgical outcome studies, progress in studying brain somatic mosaicism, and DNA methylation of human FCD tissues is reviewed and recognized in the FCD classification update. Key findings are described below.

3.1.1 | Histopathology

Bottom of sulcus (BOS) focal cortical dysplasia

FCD that is restricted in its anatomic location and extent to the bottom of a sulcus has been identified repeatedly as a surgically remediable pathology with clear implications both on the surgical approach, management, and postoperative surgical outcome.^{15,16} These lesions are identified mainly on magnetic resonance imaging (MRI). They tend to localize in the depth of frontal lobe sulci (superior frontal sulcus, inferior frontal sulcus, and central sulcus) and less frequently in the parietal or temporal lobes. Direct intralesional, intraoperative,

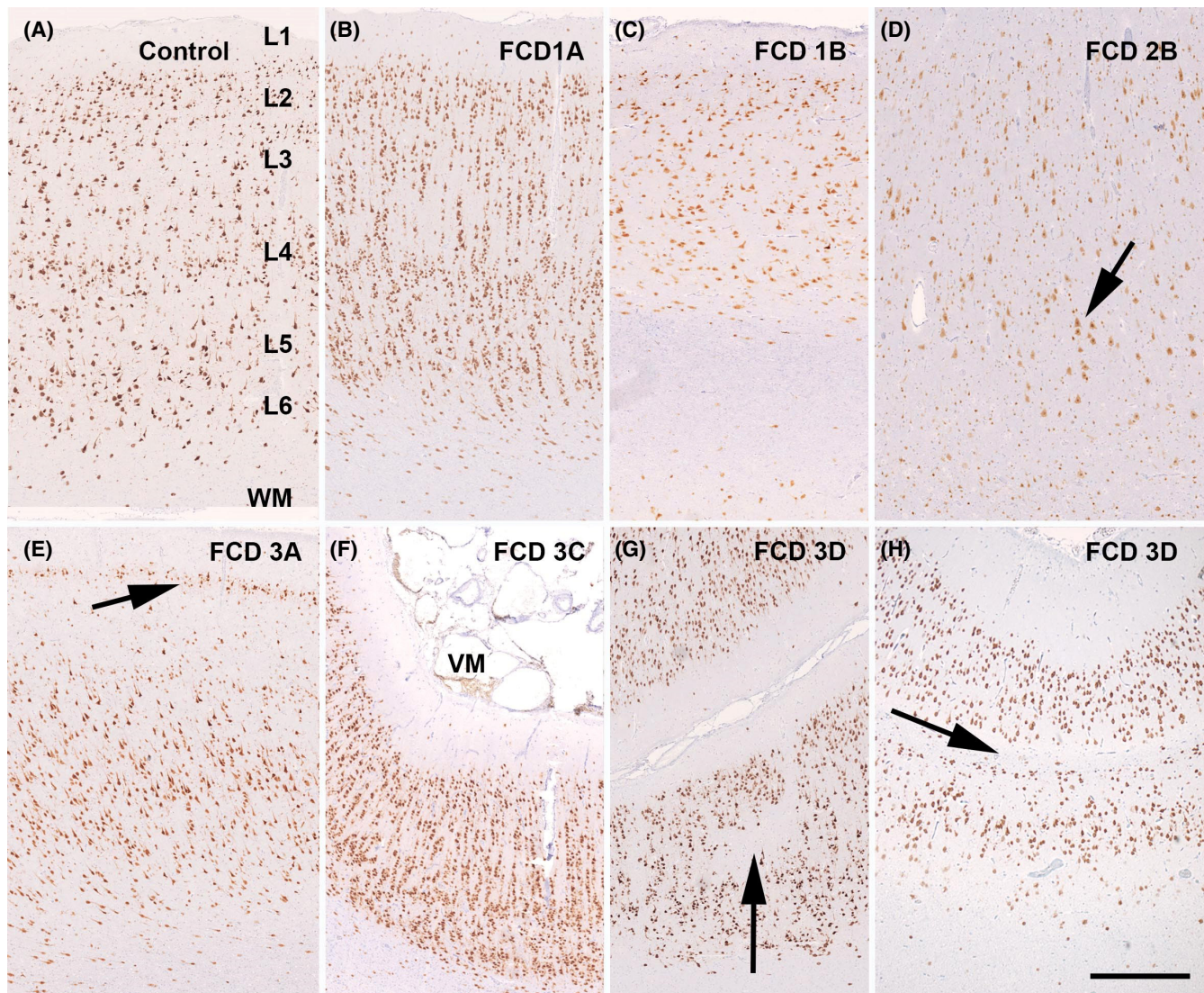


FIGURE 1 Patterns of architectural and cytoarchitectural abnormalities in focal cortical dysplasia (FCD) subtypes. A panel of classic examples taken at the same objective magnification and with same immunohistochemical stainings neuronal nuclear antibodies (NeuN). A, Normal homotypic neocortex obtained from the temporal lobe with its characteristic five neuronal cell layers (L2-L6) and the neuron sparse L1 on top and white matter at the bottom (WM). B, FCD1a of the occipital lobe is defined by abundant neuronal microcolumns with often small neurons vertically arrayed like parallel strings of pearls. C, FCD1b of the temporal lobe without any layered neocortical organization. Also note the dramatically thinned cortical diameter. D, FCD2b of the frontal lobe is characterized by lack of any cortical layering. Instead, large dysmorphic neurons appear randomly placed throughout the cortical ribbon (arrow). Balloon cells are not visible in this NeuN immunohistochemistry. E, FCD3a in the temporal neocortex of a patient with hippocampal sclerosis. Note the neuronal cell loss in supragranular layers L2 and L3 (arrow). F, FCD3c in a patient with Sturge-Weber syndrome and a vascular malformation (VM), that is, meningeal angiomatosis. The adjacent neocortex is thin and shows abundant microcolumns (as in FCD1a). G, FCD3d of the parietofrontal region in a patient with perinatal stroke. Note the patchy disruption of cortical layers (arrow). H, FCD3d of the occipital region in a boy with perinatal hypoxic injury. Note the loss of layer 4 neurons (arrow). Scale bar = 500 μ m, applies to all images

or extraoperative depth electrode electroencephalography (EEG) recordings identify a characteristic rhythmic spiking pattern in the depth of sulcus lesion.^{16,18} The complete resection of the anatomic lesion achieves seizure freedom in most patients. From a histopathological standpoint the lesions show cellular and architectural patterns of either FCDIIb (Figure 2) or, less commonly,

FCDIIa. A germline frameshift insertion in *DEPDC5* has been identified in one patient,¹⁶ and another study identified somatic pathogenic variants in mechanistic Target Of Rapamycin (*MTOR*) in six patients and heterozygous pathogenic germline variants in two (*DEPDC5* and *NPRL3*),¹⁹ thus assigning this syndrome to the spectrum of mTORopathies.

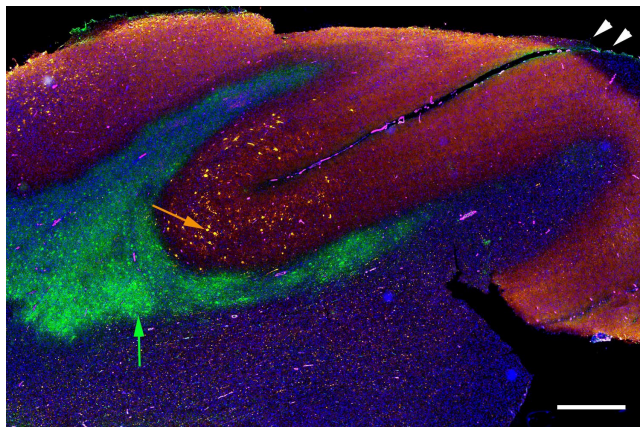


FIGURE 2 Multichannel-immunofluorescence whole slide imaging of a bottom-of-sulcus focal cortical dysplasia (FCDIIb). Dysmorphic neurons are labeled with anti-nonphosphorylated neurofilament H-specific antibodies and were concentrated at the bottom of a sulcus (orange arrow; sulcal surface indicated by small white arrowheads in the upper right). Vimentin-positive balloon cells (in green color) aggregated in the underlying white matter (green arrow). In addition, vascular myocytes expressing smooth muscle actin were visualized in magenta pseudo-color and all cell nuclei in blue color. Scale bar = 2 mm. Modified from.¹⁶

Mild malformations of cortical development with oligodendroglial hyperplasia in epilepsy (MOGHE)

An increase in oligodendroglia and heterotopic neurons in the white matter has been described as a new epilepsy-associated histopathological entity in young children with frontal lobe epilepsy.²⁰ MOGHE was also documented in patients with temporal lobe epilepsy.^{21,22} A subsequent series of 12 patients, including children (25%) and adults (75%), showed MOGHE lesions circumscribed to the frontal lobe in 6 (50%), the temporal lobe in 3 (25%), and multiple lobes in the remaining 3 patients (25%), with MRI findings like that of FCDIIa.^{23,24} Somatic brain mosaicism in the UDP-galactose transporter gene *SCL35A2* is a major etiological factor.^{13,17} These results argue for the inclusion of MOGHE as a distinct pathological entity that preferentially affects the white matter of patients with early-onset epilepsy and is amenable to epilepsy surgery.²⁵

3.1.2 | Neurophysiology

FCDII subtypes became much better characterized as clinical entities with well-defined EEG signatures in FCDIIa and IIb subtypes. The specificity of interictal patterns such as focal continuous rhythmic discharges and repetitive spiking have been suggested as possible predictors of the ictal-onset zone and of favorable postresection seizure outcome.^{3,18,26–29} Previous studies have shown that intrinsic epileptogenicity might not overlap

with the MRI-observed abnormality.^{30,31} Correlations between histopathological and neurophysiological studies, that is, intracerebral depth electrode recordings, also provided evidence for a contribution of dysmorphic neurons to interictal spikes, fast gamma activity, and ripples.³² Furthermore, seizure onset and phase-amplitude coupling in areas with dysmorphic neurons suggested preserved connectivity and was related to seizure initiation. Balloon cells showed no such association.³²

3.1.3 | Neuroimaging

MRI techniques have provided a noninvasive window for the characterization of some FCD. On the other hand, the strength of the magnet, the imaging protocol, the correlation with clinical semiology and EEG findings, and the examiner's experience are crucial for planning subsequent management.^{33,34} A negative study undertaken on a low-field MRI without using an epilepsy-dedicated protocol suggests a nonadequate imaging acquisition. This is further demonstrated using high-field MRI.³⁵ These observations highlight the need for adequate imaging studies that may transform an MRI-negative into an MRI-positive study and may fundamentally change the surgical approach, minimize the use of additional highly expensive and morbid mapping studies, and result in significantly better postsurgical seizure outcomes.^{33,34} Positive MRI changes have been described for FCDI lesions in 20% to 100% of the cases in the various publications since 2011 but the type of changes have rarely been specified further.^{36–40} In two pediatric series, one reporting on FCDIa⁴¹ and another on FCDIa and Ib,³⁸ subtle increase in white matter signal in T2 and fluid-attenuated inversion-recovery (FLAIR) were reported, with reduction of the volume of the white matter in FCDIa.⁴¹

MRI abnormalities in FCDII include abnormal gyration patterns indicated by a cortical dimple, cortical thickness changes, signal increase (mainly in FLAIR) both in the lesion and in the adjacent white matter, and gray-white matter blurring.^{6,34} The transmante sign, a linear or triangular shaped high T2/FLAIR signal extending from the lesion toward the ventricle, indicates most likely FCDIIb.⁴² Although most patients with FCDII show focal MRI abnormalities, almost one-third remain MRI negative, some of which could be due to inadequate imaging, but even 3 T imaging can be negative.^{6,43} It is tempting to speculate that MR-negative FCDII lesions belong mainly to the spectrum of FCDIIa.⁴⁴ MRI postprocessing using a morphometric analysis program (MAP) has identified structurally abnormal subtle FCD lesions.⁴⁵ In addition, a major benefit of 7 T high-field MRI with postprocessing was

reported for detection of subtle FCD lesions in patients with focal epilepsies and nonlesional 3 T MRI.³⁴ A major benefit of 7 T high-field MRI with postprocessing is the reported detection of subtle FCD lesions in 22% of patients with focal epilepsies and previous negative 3 T MRI.³⁵ Additional functional imaging modalities, such as interictal fluorodeoxyglucose–positron emission tomography (FDG-PET) and subtraction of ictal/interictal single-photon emission computed tomography (SPECT) and its co-registration with structural MRI, may add important information in patients with subtle lesions that helps to increase the confidence of the structural MRI diagnosis.⁴³

3.1.4 | Presurgical evaluation, surgical management, and postsurgical seizure outcome

Our literature survey revealed that almost half of the studies addressed surgical approaches and postoperative seizure outcomes.¹¹ These reports highlighted the difficulties in approaching FCDI: Even the use of the most invasive evaluation techniques fails to localize the epileptogenic zone (EZ) and subsequently results in no resections or failed surgical resections in many patients. These failures could also be due to more widespread epileptogenic pathology, as reported in all patients of the rare group of children with subtle unilateral hypoplasia of the posterior quadrant and FCDIa.⁴¹ On the other hand, the presurgical evaluation of patients with suspected FCDII has become more streamlined, and in some instances (FCDIIb or bottom of sulcus FCD), EZ localizations, mapping, and surgical resections with excellent results have been achieved without extraoperative invasive EEG evaluations.^{35–37} Surgical outcome studies clearly established the successes and challenges facing the current FCD classification. Excellent seizure outcomes were associated with surgical resections involving FCDII.⁵ But nonfavorable outcomes have been reported following resections of FCDI⁴¹ with the outcomes of FCDIII depending mainly on the principal lesion associated with FCD.⁴⁶

3.1.5 | Genetics of FCD

Over the last decade, there has been growing evidence that brain mosaicism plays a major role in the etiology of FCD. Pathogenic variants were discovered initially in resected tissue of large cortical malformations such as megalencephaly and hemimegalencephaly (HME) by bulk DNA copy number assessment and targeted sequencing of genes of the PI3K-AKT3-mTOR

pathway.^{47–49} Subsequent studies revealed that smaller cortical malformations, such as FCDII, are also mosaic disorders caused by pathogenic variants in the same pathway, occurring in early neuroprogenitor cells and evolving into a mutated clonal cell population.^{50–60} Currently, two distinct pathomechanisms are anticipated: (1) the glycosylation-related gene *SLC35A2* in MOGHE,^{13,17} and (2) genes belonging to the mTOR pathway (*AKT3*, *DEPDC5*, *NPRL2*, *NPRL3*, *PIK3CA*, *RHEB*, *MTOR*, *TSC1*, *TSC2*) in FCDII and HME.^{50–53,55–59} In addition, there is recent evidence that a single hit (i.e., gain-of-function variant) in activators of the mTOR pathway (e.g., *PIK3CA*, *AKT3*, *RHEB*) or in *MTOR* itself is sufficient to cause the FCDII.⁵⁶ The dysregulation of the mTOR signaling pathway provides the rational mechanistic basis for a direct link between gene mutation and brain pathology involving dysmorphic neurons, balloon cells, oligodendrocytes, and astrocytes.^{12,14,61} In contrast, a double hit with a germline and somatic loss-of-function variant in repressors of the pathway (i.e., *DEPDC5*, *NPRL2*, *NPRL3*, *TSC*) is necessary for the expression of the brain lesion. Definite somatic second-hit events, either single nucleotide variants^{19,60,62,63} or loss-of-heterozygosity (LOH)^{51,57} of the second allele leading to biallelic gene inactivation of *DEPDC5* have now been reported, validating the two-hit model for mTOR-pathway repressor genes. Even among somatic variants, the number of DNA fragments that carry the mutation in a sequencing experiment is expected to serve as a surrogate marker for the number of mutated cells in a resected tissue. Accordingly, the so-called “variant allele fraction gradient” is correlated with a “dysmorphic neuron density gradient,” with the highest variant load detected in the seizure-onset zone.^{19,63,64} Another study reported a synergistic effect of two mosaic variants in mTOR pathway activators (*RPS6* and *MTOR*) in a patient with HME.⁶⁵ In all studies, the mosaic fraction of the variants correlated with the lesion type, with greater mosaicism in HME reflecting the earlier timing of occurrence of the mutational event.⁶¹ Analysis of pools of microdissected cells demonstrated that dysmorphic neurons and balloon cells carry the pathogenic variants leading to hyperactivation of mTOR.^{19,51,64} These discoveries offer the opportunity to reshape the genetic landscape of FCD, distinguishing mTOR and non-mTOR-related FCD toward a new integrated genotype-phenotype classification.^{12,13,66} The current challenge is whether genetic findings can predict surgery outcome, the extent of the lesion, and the presence of multiple or bilateral lesions.⁶⁷ Overall mTOR-related MCD with germline or germline and somatic variants have a better surgical outcome than MCD caused by mutations in ion channel and synaptic transmission genes.⁶⁸ Two

proof-of-principle studies recently reported that brain mutations can be detected in the circulating cell-free DNA obtained from cerebrospinal fluid.^{69,70} If substantiated, this finding may allow for a genetic diagnosis before surgery, or when brain tissue is not available. Although the role of genetic testing in selecting surgical candidates and predicting surgical outcome are still debated, these findings point to the merit of including genetic testing results in the proposed integrated classification scheme update of FCD.

3.1.6 | Emerging role of epigenetics in epilepsy

There is compelling evidence that dysfunctional epigenetic processes are involved in the pathobiology of neurologic diseases and may serve as molecular indices for integrating the effects of inherited and acquired etiological factors and thus for modulating the clinical manifestations of a specific disease.⁶¹ Indeed, studies assessing DNA methylation provide evidence for a role in epilepsy.^{71,72} Genome-wide DNA methylation profiling in three different preclinical animal models identified a seizure- and etiology-specific epigenetic signature.⁷³ Furthermore, differential hierarchical cluster analysis of DNA methylation studies in resected human brain samples distinguished patients with epilepsy from controls and further classified the histopathological entities associated with a seizure phenotype.^{72,74,75} These studies not only provide evidence for disease-specific methylation signatures in focal epilepsies, but also emphasize the potential role of DNA methylation to distinguish FCD subtypes, and support the development of an integrated clinico-pathologic and molecular classification system of FCD subtypes.¹⁴ Methodological approaches aside, due consideration of clinically significant thresholds for methylation is warranted.

3.1.7 | Challenges identified in the first ILAE classification scheme

Whereas FCDIa is hitherto confirmed in a series of 19 children with early seizure onset, subtle unilateral hemispheric hypoplasia, global developmental delay, and drug resistance from seizure onset,⁴¹ a consistent clinico-pathological characterization of the patient cohort with FCDIb and FCDIc is still lacking and convincing examples are scarce in the current literature.^{36–39} In addition, Figure 2C from the original ILAE publication in 2011 showed loss of layer 4 neurons in a young boy with focal epilepsy as an example of FCDIb with horizontal dyslamination¹⁰; however, upon review, this should be

classified as FCDIIId, since there is evidence that loss of layer 4 neurons results from early (perinatal) hypoxic-ischemic injury in the occipital lobe, predominantly in boys (Figure 1H).⁷⁶ This kind of confusion raises the issue of whether cortical architectural abnormalities other than the bona fide dyslamination of FCDIa in patients with diffuse unilateral lesions mentioned above⁴¹ truly represents “dysplastic” abnormalities or simply variable architectural changes. Furthermore, histopathology of FCDIc was never described before the ILAE classification in 2011, and it quickly developed into a “wastebasket” of cases clinically suspected as FCD with no or very subtle MRI findings.¹¹ It is important to note that FCDI subtypes also lack comprehensive publications beyond isolated reports in very small patient series that characterize their molecular genotype.⁷⁷

Although FCDIII and its four subtypes acknowledged the role of the abnormal architectural organization of the neocortex in the immediate vicinity of congenital epileptogenic lesions, such as developmental brain tumors, vascular malformations, or pre- and perinatal infarction, its significance in hippocampal sclerosis and postnatally acquired brain lesions was also addressed by comments in the 2018 ILAE survey. FCDIII patterns were classified initially as FCDI with architectural disorganization in patients with hippocampal sclerosis or developmental tumors following the Palmini classification scheme. Our current literature review did not detect increased scientific engagement into these FCDIII entities. In contrast, imaging features suspected as FCD in temporal lobe epilepsy, that is gray-white matter blurring and temporopolar atrophy, were shown to represent secondary alterations in white matter, without FCD.^{74,78} The diffuse and infiltrative behavior of many epilepsy-associated glioneuronal tumors can mimic FCDIIb. Systematic histopathological reviews using refined panels of immunohistochemical markers, that is, CD34, BRAFV600E, and microtubule associated protein 2 (MAP2),^{79–81} did not support any specific FCDIIb patterns. Less-conflicting results were published for FCDIIc and FCDIIId phenotypes.^{82,83} Sturge-Weber syndrome almost always shows histopathological signs of complex architectural dysplasia consisting of radial and vertical disorganization of the neocortex, that is, FCDIIc.^{82,84} This FCD subtype is less frequently detected with cavernomas and arteriovenous malformations.⁸⁴ However, hypertrophic neurons can often be encountered in affected cortices but should not be confused with dysmorphic neurons in FCDIIa.⁸² Perinatal hypoxemia, bleeding, and inflammatory disorders are the most common principal lesions associated with FCDIIId. These data strongly suggest progressive alterations of postmigratory plasticity as the cause of

associated FCD phenotypes.⁸⁵ Notwithstanding these considerations, the true dysplastic nature of all FCDIII subtypes needs to be further elucidated based on new scientific developments in the coming years. This issue will also benefit from careful correlational studies indicating whether resection of the abnormally laminated cortex associated with the “principal lesion” impacts on surgical outcome—or if the latter is related mostly to resection of the principal lesion, that is, hippocampal sclerosis, tumor, or vascular malformation.⁴⁶

3.2 | The 2018 online survey of the ILAE task force

A total of 367 members of the international epilepsy community responded to the ILAE online survey. Details of the survey results can be found in the Appendix S1. Thirty-two percent of the respondents identified themselves as neuropathologists; 38% as neurologists; and 46% as epileptologists (with multiple assignments possible). Most of the responders (75.1%) stated that they were using the ILAE classification in their clinical practice or research. The newly suggested FCD type (FCDIII) in the 2011 classification was used by more than 82% of the respondents.

The responses highlighted three main areas for potential improvement: genetics, mMCD, and FCDI. More than one third (35%) of respondents were using genetic testing from blood and brain tissue for the diagnosis of FCD. More than 60% of the respondents suggested an incorporation of genetics in the workup of patients with suspected FCD (60%). The survey found that the diagnosis for mMCD remains open to subjective interpretation and may vary from center to center due to the lack of universally adopted criteria, and more than half of the respondents suggested the addition of mMCD to a revised classification proposal. The survey respondents (48%) identified the need for a better histopathology definition of FCDI subtypes and their differentiation from normal human neocortical architecture.

3.3 | Results of the histopathology and genetic agreement study 2018–2020

As reported in published literature, the agreement study showed that the histopathological identification of FCD subtypes could be improved using a selected immunohistochemistry protocol.¹³ Consistent with previous ILAE recommendations, the proposed antibodies include neuronal nuclear antigen (NeuN), nonphosphorylated neurofilament, vimentin, Olig2, CD34, and

MAP2 antibodies.⁷⁹ NeuN immunostaining was most helpful in studying homotypic or heterotypic patterns of the human neocortex compared to architectural dysplasia in FCDI. Antibodies directed against nonphosphorylated neurofilament (SMI32) are sensitive markers of dysmorphic neurons in all FCDII subtypes. Olig2 antibodies were helpful for recognizing the cases with MOGHE. In addition, the interobserver agreement increased further to a kappa value of 0.65 (good) with the availability of all genetic testing results, that is, 7 of 22 cases revealed brain somatic mutations in *MTOR*, *AKT3*, or *SLC35A2*, or germline mutations in *DEPDC5* and *NPRL3*.¹⁵ Of interest, the agreement study highlighted cases where “no FCD” was concluded by most reviewers after all the immunostainings and negative gene testing results were made available. Acknowledging a “no definite FCD on histopathology” option in the FCD classification update may reduce, therefore, the tendency of neuropathologists to “overdiagnose” FCDI subtypes.¹³ The “no definite FCD on histopathology” category should be used only in cortical epilepsy with a clinical suspicion of FCD, and when there is: (1) an abnormality of cortical organization that remains ambiguous and histopathological findings are not compatible with FCDI, FCDII, or FCDIII; or (2) there is incomplete surgical removal or sampling of the tissue.¹³ On the other hand, the results confirmed the challenge in differentiating FCDI and FCDIII subtypes from normal variations in cortical architecture. The study further revealed that lentiform heterotopias in the white matter of the temporal lobe, that is, the superior temporal gyrus, which were classified as FCDIIIa in the 2011 classification scheme, represent a normal anatomic feature of the claustrum.¹³

All of this new knowledge indicated that the unidimensional nature of the current ILAE classification scheme will not unequivocally allow for the integration of an ever-increasing and clinically relevant, multifaceted pool of information. The TF proposes an update for the FCD classification, therefore, that includes: (1) a panel of immunohistochemical staining²; (2) two additional histological categories: white matter lesions and “no definite FCD on histopathology” (Table 1); and (3) a multi-layered classification scheme (Table 2) adding the level of genetic and neuroimaging findings to obtain a comprehensive, reliable, and integrative genotype–phenotype diagnosis.

3.4 | Consensus proposal for a pathology update and the creation of a multilayered classification of FCD

The proposed histopathology update to the ILAE classification of FCD (Table 1) and the multilayered classification

TABLE 1 The histopathology-based FCD classification update (new categories highlighted in gray)

FCDI ^a	FCDIa abundant microcolumns	FCDIb abnormal layering	FCDIc vertical and horizontal abnormalities
FCDII ^a	FCDIIa dysmorphic neurons		FCDIIb dysmorphic neurons and balloon cells
FCDIII ^a	FCDIIIa cortical dyslamination associated with hippocampal sclerosis	FCDIIIb cortical dyslamination adjacent to brain tumor	FCDIIIc cortical dyslamination adjacent to vascular malformation to lesion acquired during early life, e.g., stroke
White Matter ^a	mMCD ^b with excessive heterotopic neurons ^a		mMCD with oligodendroglial hyperplasia in epilepsy (MOGHE) ^c
No definite FCD on histopathology ^a	Abnormality of cortical organization remains ambiguous and histopathological findings not compatible with FCDI, II or III ^d		

^aThe TF recommends applying immunohistochemical staining for the detection of architectural abnormalities and FCD subtypes, i.e., antibodies directed against neuronal nuclear antigen (NeuN), neurofilaments, vimentin, microtubule associated protein 2 (MAP2), CD34, OLIG2, glial fibrillary acid protein (GFAP), or alpha B-crystallin. The diagnostic term of “not otherwise specified (NOS)” shall be used if the microscopic diagnosis is not based on appropriate immunohistochemical staining, e.g., FCD type I (NOS).

^bMild malformations of cortical development (mMCD): not associated with any other principal lesion, such as hippocampal sclerosis, brain tumor, or vascular malformation.

^cAlthough mild malformations of cortical development with oligodendroglial hyperplasia (MOGHE) is primarily a white matter abnormality, abnormal cortical folding can be seen on MRI, and the combination of the two is often interpreted as FCD.

^dNo definite FCD on histopathology: a descriptive report is recommended to highlight anatomic ambiguities in clinically suspected cases of FCD.

scheme of FCD (Table 2) were achieved following multiple iterative discussions during the various meetings of the TF (as above) until unanimous agreement was reached on all items.

3.4.1 | Update of the histopathology-based classification scheme of FCD

FCDI remains a specific histopathological category characterized by architectural disorganization of the neocortex due to compromised developmental maturation, and without evidence of any additional principal epileptogenic lesion in the brain (as confirmed by MRI or histopathology). This definition will not deviate from the 2011 classification scheme.¹⁰

FCDIa is histopathologically defined by an abundance of neuronal “microcolumns” that predominate in any low-power objective microscope magnification, to be confirmed by immunohistochemical staining with antibodies directed against NeuN (Figures 1B and 3). Heterotopic neurons in the white matter also invading the area of U fibers are additional hallmarks of the disease.⁸⁶ A clinico-pathological correlation has been established in a series of 19 children with severe drug-resistant posterior quadrant epilepsy.⁴¹ This *FCDIa* presentation is, however, a less-frequent disease condition representing only 4% of 500 operated children in this study and 14.6% of all FCD cases. Reported mutations in the *SLC35A2* originally assigned to *FCDIa*^{51,60,87,88} were reviewed and re-assigned to MOGHE in all cases¹⁷ (see below). The classification of neuronal microcolumns as ILAE *FCDIa* follows the microscopic guidelines described in the 2011 classification scheme and should always be confirmed by immunohistochemical staining using NeuN (Figure 1A). A second histopathology feature is the excess of heterotopic neurons in the white matter, as defined by Mühlebner and colleagues,⁴⁴ and should be confirmed using MAP2 immunohistochemistry. Dysmorphic neurons or balloon cells or other principal histopathology lesions will exclude this diagnosis. DNA methylation array analysis from routine formalin-fixed paraffin-embedded (FFPE) tissue may support the diagnostic yield in the near future.^{41,74} Accordingly, the coexistence of an excessive microcolumnar organization with heterotopic neurons in the white matter and a DNA methylation class distinct from other FCD subtypes was convincing enough for the TF to not abandon the *FCDIa* category. Similar patterns of microcolumnar organization of the neocortex were also described in children with genetic defects or inborn metabolic diseases, although with more widespread distribution.⁸⁹ The TF noted that such microcolumnar organization resembles neuronal radial migration streams during corticogenesis⁹⁰ and may result

TABLE 2 Integrated multi-layered FCD classification scheme^a

Layer 1A: Histopathology diagnosis ^b	Brief description of architectural and/or cytoarchitectural histopathology findings using H&E and appropriate immunostainings
Layer 1B: ILAE histopathological subtype ^b	Assign histopathology findings to the ILAE classification update (see Table 1)
Layer 2: Genetic findings ^c	Describe genetic findings, methodology used, and tissue source, i.e., fresh-frozen brain tissue and paired peripheral blood samples or formalin-fixed-paraffin-embedded (FFPE) tissue only. If genetic testing is not available, please indicate it as “not available (NA)”
Layer 3: Neuroimaging findings ^d	Whether MRI is normal or abnormal. If a focal abnormality is found, specify how it was found: visual analysis, postprocessing, etc. Describe its anatomic location (lobe, gyrus, bottom of sulcus), its characteristics (changes in gyri and sulci morphology, cortical/subcortical hyperintense T2/FLAIR signal, transmantle sign, blurring of gray matter/white matter interface, cortical thickening, etc.), include information on the scanner strength and imaging protocol used
Integrated diagnosis ^e	Give information if the lesion was MRI positive or negative. Use the ILAE classification scheme and specify genetic findings. <i>Example:</i> MRI positive bottom-of-sulcus focal cortical dysplasia IIb (right superior frontal gyrus) with brain somatic <i>MTOR</i> mutation

^aIllustrative case studies on the use of the proposed multi-layered approach could be found in the supplemental case series in the Appendix S1.

^bThis layer refers to the reporting of a neuropathologist experienced in the field of epilepsy surgery.

^cThis layer refers to the reporting of a geneticist experienced in the field of epilepsy surgery.

^dThis layer refers to the reporting of a neurologist/neuroradiologist experienced in the field of epilepsy surgery.

^eThe integrated diagnosis should be assembled, e.g., during a postsurgical patient management conference led by the epileptologist in charge of the patient following a comprehensive multidisciplinary review of all available diagnostic reports.

from delayed or arrested maturation at mid-gestation (Figure 3).

FCDIb or FCDIc: Until now, there are no specific clinico-pathological correlations reported for patients with FCDIb or FCDIc. The TF recommends maintaining these subtypes in the classification update with the hope that future research would establish clinically meaningful phenotypes. Nonetheless, FCDIb shall microscopically reveal the disruption of the six-layered anatomical organization, that is, horizontal architectural dysplasia (Figure 1C). The diversity of Brodmann areas in the human homotypic and heterotypic neocortex must be taken into consideration, however. Findings reminiscent of FCDIb shall therefore be confirmed by immunohistochemistry. In cases without these stainings being available, no further subtyping is recommended, and the diagnosis should read as FCDI (NOS – not otherwise specified). The same applies for FCDIc, which is characterized by a mixture of horizontal and vertical layer abnormalities. These patterns can more often be

identified in FCDIIc and FCDIIId (see below) and associated principal lesions must be excluded in the differential diagnostic workup, including MRI inspection of brain regions not included in the surgical resection sample.

FCDII (Figure 4) are the most common MCD in epilepsy surgery case series representing ~9% of all cases, and 51% of histopathologically confirmed cases are localized to the frontal lobe.⁴ This assessment is not different from the 2011 classification scheme. Seizure onset starts at a mean of 5 years of age. FCDII are characterized by the presence of dysmorphic, often cytomegalic neurons.⁴⁴ Their shortest diameter is above 25 µm and significantly larger than any typical pyramidal cell in age- and location-matched postmortem controls.⁴⁴ Although glia are not part of the histopathological definition of FCDII, glial cells also are dysmorphic and often enlarged. FCDIIb is further distinguished from FCDIIa by the additional presence of balloon cells and a compromised oligodendroglial cell population.⁴⁴

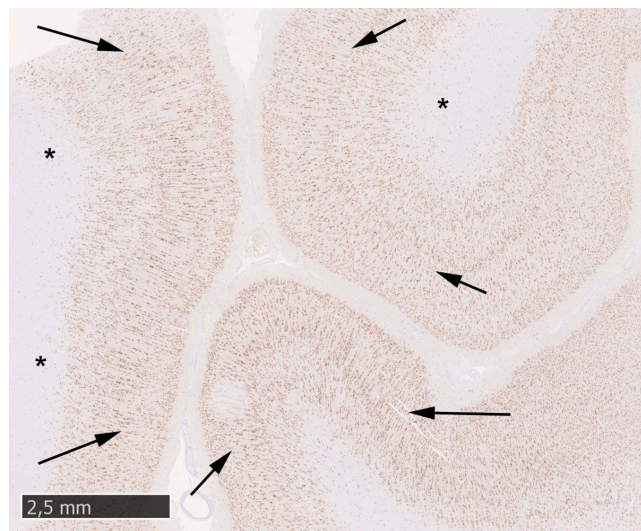


FIGURE 3 Histopathological hallmarks of FCDIa. An 18-year-old female patient. Cognitive decline with onset of daily and medically intractable seizures at age 10 years. Arrows: note the multiple regions with abundant microcolumnar organization of the neocortex, which is partially also thinned (<2.5 mm). Asterisks: Abundant heterotopic neurons in the white matter of the same gyri. Neuronal nuclear antigen immunohistochemistry of a 4- μ m thin FFPE section

Balloon cells are of mixed lineage, expressing both neuronal and glial protein transcription products, and they often circumvent the area with accumulated dysmorphic neurons (Figure 2). Dysmorphic neurons are the source of abnormal electrical activity, whereas balloon cells are not.^{32,91} FCDII often presents with additional architectural dysplasia, that is, loss of homotypic six layers when admixed with normal pyramidal cells (Figure 1D). The affected neocortex also has a reduced cell density, which is more significant in FCDIIb than in FCDIIa. MRI-negative FCDII lesions are likely to belong to the FCDIIa subtype, as abnormalities in cortical thickness, cell density, myelination, and oligodendroglial cell population are often subtle or remain intact.⁴⁴ Sixty percent of FCDII present with brain somatic mutations in the mTOR pathway, mostly in the *MTOR* gene in the FCDIIb subtype.⁵¹ Loss-of-function germline mutations have been detected mostly in FCDIIa with a second hit mutation, that is, loss of heterozygosity, inactivating the second allele of *DEPDC*.^{19,55,63} Of patients with FCDII, 67.4% are free from disabling seizures 5 years after surgery, and 39.4% of patients also have discontinued antiseizure medications.⁵

FCDIII represents abnormal architectural organization of the neocortex in the immediate vicinity of epileptogenic lesions, such as hippocampal sclerosis (FCDIIIa), developmental brain tumors (FCDIIIb), vascular malformations (FCDIIIc), or any other lesion acquired during early life (FCDIIId), that is, pre- or perinatal infarction,

bleeding, and inflammation. This assessment has not been changed from the 2011 classification scheme. Architectural abnormalities are predominantly horizontal in FCDIIIa, defined by loss of layer 2 and 3 neurons in patients with long-term epilepsy and hippocampal sclerosis⁹² (Figure 1E). A mixed phenotype with horizontally and vertically compromised cortical layering is often encountered in FCDIIIc, that is, Sturge–Weber syndrome^{83,84} (Figure 1F). FCDIIId with loss of layer 4 is observed predominantly in boys with perinatal hypoxic brain injury of the occipital lobe⁷⁶ (Figure 1H). Dysmorphic neurons are not a feature of FCDIII subtypes. Enlarged pyramidal neurons can be detected microscopically, however, in many cases. Their retained anatomic orientation qualifies them as hypertrophic rather than dysmorphic neurons.^{76,82,83} The diagnosis of FCDIIIb is rare and requires the immunohistochemical assessment to exclude glioneuronal tumor tissue infiltrating the neocortex.^{10,79,81,93} There is no known genetic cause for FCDIII. Postsurgical seizure outcome is similar to that for patients with the same principal lesions irrespective of the presence or absence of associated FCDIII.⁴⁶

Mild malformations of cortical development (or mMCD; Figure 5) is microscopically recognized by an excess of heterotopic neurons in the white matter—above 30 neurons per mm^2 (Figure 4B)—and not being associated with any other principal lesion. Densities of $<30/\text{mm}^2$ were shown to be unlikely to be mMCD in a study using automated quantitation of normal white matter NeuN-positive neurons in 142 epilepsy resections compared to controls that confirmed densities.⁹⁴ mMCD was first defined in the Palmini classification,⁸ also included in the 2011 ILAE scheme, and its definition will not be changed or modified herein, due to lack of consensus on their diagnostic features and on their potential epileptogenicity. mMCD can be detected in about 3% of (mainly adult) patients according to a large surgical case series.^{4,5} MAP2 immunohistochemistry identifies increased neuropil of the white matter above 10% (Figure 4B), which likely represents synaptic plexi.^{44,86} Persisting neurons in cortical layer 1, that is, mMCD type I of the Palmini classification scheme, have not been confirmed in surgical case series and will not be included herein. mMCDs are reported mainly as MRI negative⁹⁵ but this is not the case in all reports.^{96,97} Reported postsurgical outcomes for mMCDs are highly variable, ranging from 0 to 75% seizure freedom.^{51,60,95,97,98} However, a large European-wide epilepsy cohort of 9147 cases reported 45% of patients achieving seizure freedom at 2 years postresection of mMCD.⁵ DNA methylation array analysis from routine FFPE tissue may increase the diagnostic yield in the near future.⁴¹ Building on the most recent scientific advances, the TF proposes to include lesions compromising the white matter as new

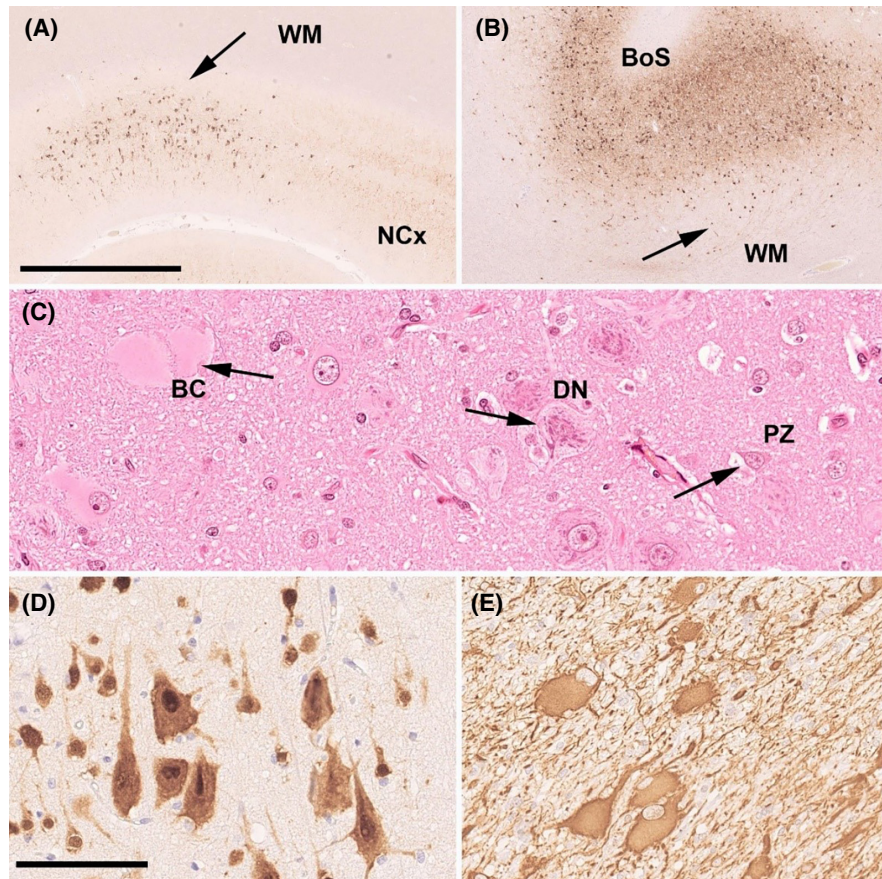


FIGURE 4 Histopathology findings in ILAE FCDIIa and IIb. A, A 42-year-old female patient with frontal lobe epilepsy since age 5 years and histopathologically confirmed FCDIIa. The arrow points to the sharp border between the cortical FCD and the normal-appearing white matter (WM). Normal six-layer neocortex (NCx). Neurofilament-immunohistochemistry, scale bar = 2,5 mm (applies also to B). B, A 19-year-old female patient with frontal lobe epilepsy since age 9 years, and histopathologically confirmed FCDIIb at a bottom-of-sulcus (Bos). The boundary toward the white matter is less well pronounced (arrow). C, Hematoxylin and eosin (H&E) staining at higher magnification of FCDIIb with opalesque balloon cells (BCs), enlarged dysmorphic neurons (DNs), and normal appearing pyramidal cells (PZs). D, Nucleonuclear antigen immunohistochemistry demonstrating clusters of anatomically abnormally positioned dysmorphic neurons next to pyramidal cells (on the left) in FCDII. E, Balloon cells frequently stain with antibodies directed against vimentin, but also pS6 or alpha B-crystallin (not shown). Scale bar = 100 μ m, applies also to C and E

diagnostic categories, that is, mMCD and MOGHE, as specified below.

Mild malformations of cortical development with oligodendroglial hyperplasia in epilepsy (or MOGHE) is defined by an increase in heterotopic neurons in the white matter and oligodendroglial cell densities above 2200 Olig2-immunoreactive cells per mm^2 ^{20,22–24,99–101} (Figure 5D). Reported cases involve young children with frontal lobe epilepsy, or temporal plus epilepsy, with a median seizure onset at age 2 years (range 0.3–13 years).²⁰ In a retrospective clinical study of 20 patients with MOGHE, postoperative seizure outcome depended largely on the extent of the resection, with a good Engel class I outcome reported for all patients with large resections.^{24,25} MOGHE represents a distinct mMCD subtype, with 45%–100% of studied patients harboring *SLC35A2* somatic variants.^{13,17} One study

also showed that *SLC35A2*-mutated brain tissue had an aberrant pattern of glycosylation.⁸⁸ Most pathogenic *SLC35A2* variants are nonsense or frameshift variants leading to loss-of-function of the protein in the mutated cells, that is, oligodendroglia and heterotopic neurons in the white matter. These findings demonstrated that somatic brain-only variants in the UDP-galactose transporter gene *SLC35A2* are a major etiological factor and may be linked to the pathogenesis of MOGHE.

No definite FCD on histopathology

The TF suggests adding “no definite FCD on histopathology” as a new category to the updated histopathology-based classification scheme when the anatomic orientation and organization of the surgical specimen remains ambiguous, and an abnormality cannot be evidenced by strict histopathology measures, for

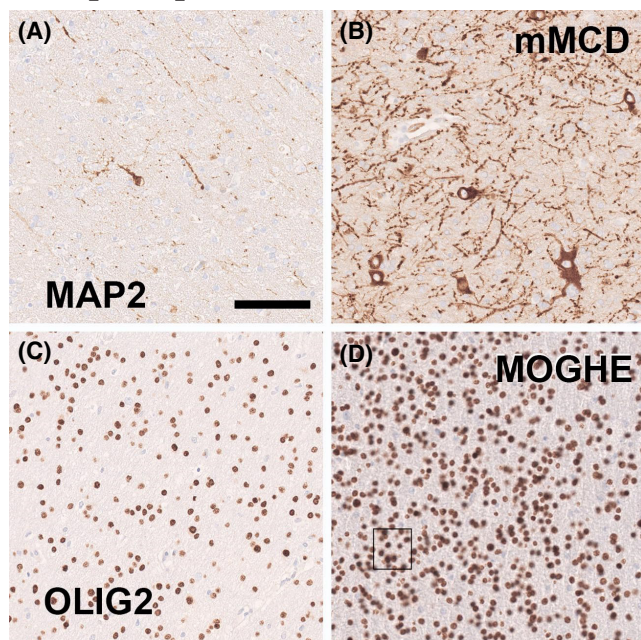


FIGURE 5 Histopathology findings in mild malformations of cortical development (mMCD) and mild malformations of cortical development with oligodendroglial hyperplasia in epilepsy (MOGHE). A, Microtubule associated protein 2 (MAP2) immunohistochemistry from white matter obtained from a patient with temporal lobe epilepsy (TLE) demonstrating the rare presence of heterotopic neurons. Scale bar = 100 μm . The optical field represents $\sim 0.25\text{mm}^2$ ($500 \times 500\text{ }\mu\text{m}$), which applies also to B-D. B, MAP2 immunohistochemistry demonstrating abundance of heterotopic neurons in mMCD. The visual contains eight neurons accounting to >30 neurons/ mm^2 as defined for mMCD. C, Olig2 immunohistochemistry showing an almost normal density of oligodendrocytes ($<1000\text{mm}^2$ ²⁰). Image taken from a region adjacent to MOGHE, as shown in D. D, Olig2 immunohistochemistry showing a significant increase of oligodendroglial cell density above $2200/\text{mm}^2$, a cutoff published by Schurr et al. in 2017. In this example, the density would account for even more than 10 cells in a microscopically measurable optical field of $50 \times 50\text{ }\mu\text{m}$ (black square)

example, the resemblance with homotypic or heterotypic Brodmann areas, an oblique plane of sectioning, implantation of intracerebral depth electrodes, or perioperatively introduced tissue artifacts. Notably, the use of IHC staining is mandatory to confirm the absence of any FCD, that is, NeuN and MAP2. The TF further recommends describing any anatomic ambiguities in the pathology report.

3.4.2 | An integrated, multi-layered, genotype–phenotype approach to diagnose FCD

The TF proposes a multi-layered integration of histopathology with the level of genetic and neuroimaging

findings to obtain a comprehensive and reliable genotype–phenotype diagnosis (Table 2). The various layers of the classification cover current knowledge and, at the same time, enable the seamless inclusion of future knowledge. This explicit, multi-layered integration enhances clarity and can facilitate broader international communication and collaboration in this field.

Layer 1: The histopathological assessment

The neuropathological workup of cortical tissue obtained from epilepsy surgery remains the gold standard in diagnosing any focal epileptic disorder.⁸⁰ It is recommended to apply the updated ILAE classification scheme presented in Table 1. The neuroanatomical *punctum maximum* of the lesion can be added to the report if the neurosurgeon provided anatomic labels or tissue landmarks can be microscopically identified.⁸⁰ The benefit of immunohistochemistry in supporting hematoxylin and eosin (H&E) staining for a reliable diagnostic workup has been confirmed in many histopathology agreement trials and the recent iterative ILAE TF study.^{13,102,103} Therefore, the TF recommends the use of a standardized panel of IHC markers to confirm abnormal histopathology patterns that should, in turn, be specified in the report (see supplemental case series). Finally, the written histopathology report should be concise to allow unequivocal integration with all other layers of the FCD classification scheme (Table 2).

Layer 2: Integration of molecular-genetic results

The second layer integrates genetic findings as an objective measure for the diagnosis of FCD, thereby specifying the patient's FCD diagnosis. Although genetic testing of somatic and germline mutations for FCD is not yet available in most epilepsy centers, it is a piece of important information for the genetic consultation whether FCD patients carry pathogenic somatic (not inherited, not transmissible) or germline (possibly inherited and transmissible) variants. Although genetic testing from surgical human brain tissue can be performed either by a neuropathologist experienced in molecular pathology and/or a geneticist, the TF recommends the following laboratory protocols for a reliable detection of low-level brain mosaicism in FCD: (1) extract DNA from lesional brain tissue microscopically confirmed by an experienced neuropathologist to enhance the diagnostic yield, that is, from fresh frozen or FFPE tissues; (2) use hybridization capture and high-depth next generation sequencing of $>1000\times$ reading depth of FCD relevant genes⁶⁰; (3) use somatic mutation callers, for example, *MuTect2*, *Replow*, *Strelka2*¹³; and (4) validate candidate variants using orthogonal technology, for example, droplet digital polymerase chain reaction or target-site specific amplicon sequencing (for more information see supplemental material).

Nine genes have been reported to cause *canonical* FCDII: *AKT3*, *DEPDC5*, *MTOR*, *NPRL2*, *NPRL3*, *PIK3CA*, *RHEB*, *TSC1*, and *TSC2*. *SLC35A2* should be included in the panel in order to differentiate MOGHE^{13,17,61} from its most common differential diagnosis: FCDIa.⁴¹ The diagnostic yield using such gene panel sequencing from routine FFPE or frozen tissue ranges from 32% when assessing various epilepsy-related lesions^{13,60} to 45% in patients selected for MOGHE,¹⁹ and 63% in patients with hemimegalencephaly or FCDII.⁶⁰ The second diagnostic layer of genetic analysis should conclude with a statement about: (1) the type of findings, for example, gain or loss of function mutation of a particular gene; (2) the location of the mutation; (3) the sample used, that is, blood, tissue FFPE vs fresh frozen; and (4) the methodology used. In addition, DNA methylation array analyses from routine FFPE tissue should be added if done as it may support the diagnostic yield.^{14,41,72,74,75} If genetic testing is not available, the recommendation of the TF is to indicate it as “not available (NA)” in the final report.

Layer 3: Integration of neuroimaging findings

MRI is an essential cornerstone in the workup of patients with focal epilepsy.^{6,57,104} The recommendations for the use of structural MRI and the need for optimized data acquisition and quantitative analysis protocols early in the treatment of epilepsy were recently highlighted by the ILAE Neuroimaging Task Force^{6,104} and reporting should be performed by a neuroradiologist and/or a neurologist/epileptologist experienced in the presurgical evaluation. The information obtained from visual analysis of signal characteristics in any suspicious lesion, with or without postprocessing, its location, and its extent are fundamental to the surgical approach in these patients. In addition, certain MRI findings could be predictive of the FCD type and sub-type, for example, the presence of a “transmantle sign” in FCDIIb.⁴³ Bottom of sulcus (BOS) FCD is often recognized through high-resolution imaging but not necessarily by the examination of histopathology samples (e.g., when anatomic landmarks are not available). BOS is an imaging entity, such as “transmantle FCD,” that has the crucial value of anticipating (1) a histopathological subtype (FCDII, usually FCDIIb), (2) the possibility of a low-cost, straightforward noninvasive presurgical evaluation, and (3) a surgical strategy (gyral resection extending to the BOS under intraoperative electrocorticographic recordings with depth electrodes). Its inclusion in the multi-layered classification scheme is rather an example of the utility of this system as a predictor of the histological type. We have exemplified the BOS case further in the manuscript to appropriately address the referee's concern.

MRI could be negative in some histopathologically confirmed FCDIIa or in cases with FCDI, mMCD, or

MOGHE. However, it is important to note that a good proportion of negative MRI is due to substandard acquisitions coupled with interpretation of images without considering all available seizure semiology and EEG data.^{6,34,44} In addition, ultra-high-field MRI could further advance the diagnostic yield in FCDI and FCDII and should be used in “MRI-negative” cases whenever possible.^{34,105}

For these reasons, the TF recommends the inclusion of the following MRI details as the third layer in the revised FCD classification scheme: (1) a description of the MRI abnormality (signal and morphological details, if applicable), its anatomic location, that is, side, lobe, gyrus, and topographical location, for example, the crown of a gyrus vs bottom of the sulcus; (2) the field strength of the magnet and the imaging protocol used⁶; and (3) the analysis method, for example, visual, postprocessing, or supported by machine learning. This information is typically provided by a neuroimaging specialist and discussed by the epilepsy team during a presurgical patient management conference. For more information see supplemental material.

Layer 4: Integrated diagnosis

As stated in Table 2 and illustrated in the Appendix S1, this layer is the summary of all the available pertinent features described in the first three layers of the proposed FCD classification. The TF recommends that the integrated diagnosis should state the following: (1) Whether the MRI is positive or negative, (2) the histopathological type/subtype of the lesion and its anatomic location, and (3) the genetic finding (negative or positive, and type of mutation). It is the hope of the TF that the integrated diagnosis will be used as a tool for clinical management and outcome prediction. The compilation of the various layers of information for the proposed classification scheme is the job of the treating physician (e.g., neurologist, epileptologist, neurosurgeon). This may be the product of another postoperative multi-disciplinary team conference, much like the preoperative assessment of patients with FCD. The treating physician is the final arbiter in summarizing the results of the surgical evaluation, the multidisciplinary patient management conference (PMC), and its recommendations. Although a postsurgical PMC is desirable for the purpose of applying the multi-layered classification, the TF recognizes that this may not be practical in many clinical settings. Therefore, a key aspect in applying the multi-layered classification is the systematic accrual and documentation of the necessary data pertaining to each of the four layers in each patient. The treating clinician will then be able to assemble the elements into an Integrated Diagnosis.

An evaluation of the significance of each layer in the context of the integrated system should move the field

closer to the practice of precision medicine in the management of patients with epilepsy and FCD, and which will be further studied by an ILAE task force during the term 2021–2025.

4 | DISCUSSION

The TF concludes its work on updating the international consensus ILAE classification scheme of FCD with the proposal of an integrated, multi-layered, genotype–phenotype approach to diagnose FCD. FCD diagnosis should be concise and integrate the most relevant findings obtained from the neuropathological tissue workup, histopathology assessment (Level 1), genetic analysis of resected tissue (Level 2), and the presurgical MRI findings (Level 3). The TF acknowledges that not every center will have access to advanced neuropathological, neuroimaging, or genetic analyses techniques. However, information on each of the three layers should be incorporated as it is available in different settings. This recommendation constitutes a target goal to achieve adequate proficiency in epileptology. It is hoped that it will also support the allocation of sufficient resources to diagnose and appropriately manage patients with difficult-to-diagnose and difficult-to-treat focal epilepsy.

The proposed update to the histopathological classification considers the new knowledge, for example, MOGHE, *SLC35A2* altered, and recognizes the category of “*no definite FCD on histopathology*.” This diagnosis should be used only when there was a clinical suspicion during the presurgical evaluation of the patient, and the microscopic tissue assessment cannot conclusively confirm the diagnosis of any FCD subtype as defined in the current classification scheme. It is the hope of the TF that the inclusion of this category will help to decrease the number of samples that may be inappropriately classified as FCDI, and eventually help to better characterize the clinical, imaging, and electroencephalographic features as well as the postsurgical outcome of FCD, and which remained a major challenge since the Palmini classification of 2004.⁸ Neurosurgical sampling errors should also be taken into consideration, for example, incomplete surgical resection, laser ablation, thermocoagulation, and cavitron ultrasonic surgical aspirator tissue homogenization, when the histopathology report cannot confirm a clinically suspected lesion. The latter may result from the detection of neuroimaging abnormalities interpreted clinically as FCD, for example, hyperintense signaling in FLAIR sequences. A typical example is that of temporopolar atrophy with signal hyperintensity and gray-white matter blurring in a patient with hippocampal sclerosis. These cases have been systematically studied by high-power MRI and electron

microscopy and demonstrated white matter lesions secondary to reduction in axonal density.^{78,106} Indeed, 67.7% of surgical specimens with no histopathologically detectable lesion were obtained from the temporal lobe.⁴ Despite the lack of any histopathological findings, 51.6% of patients remain free from disabling seizures 5 years after surgery.⁵ This unprecedented percentage of seizure-free patients with no FCD warrants further research to identify possible new disease entities, for example, MOGHE,²⁰ or seizure-susceptible brain somatic mosaicism amenable to surgical treatment.

Adding the level of genetic information to the diagnosis will have substantial impact on standardizing the diagnosis of FCD subtypes. It directly addresses the underlying pathomechanism and opens new avenues for personalized medicine. Further research and clinical trials are mandatory to achieve this goal, which has been often compromised by insufficiently characterized or classified patient and tissue cohorts. Genetic testing should increasingly become a standard element in all scientific publications addressing this matter. However, if genetic testing was not performed at the final step of integrating the FCD diagnosis, it should be noted that it was not available (NA).

The importance of neuroimaging in the clinical workup, surgery planning, and clinical management of patients with focal epilepsies due to FCD has been clearly recognized in this report. It is the strong recommendation of the TF to integrate this layer of information into the integrated, multi-layered, genotype–phenotype diagnosis. Imaging (MRI) is the first noninvasive window to the identification of focal FCD lesions and, in some instances, point to their neuropathology (e.g., FCDIb or MOGHE), inform surgical planning/type of intervention (e.g., extraoperative invasive EEG in FCDI vs intraoperative mapping in bottom of sulcus dysplasia and some FCDII), and outcome (e.g., excellent outcomes in bottom of sulcus dysplasia).

5 | CONCLUSION

This multi-layered approach resembled the currently proposed World Health Organization (WHO) classification scheme of tumors of the nervous system, which also integrates the histopathology diagnosis with genetic and/or DNA methylation markers to achieve a reliable, clinically relevant, and therapeutically targetable tissue diagnosis. Of note, the layer of MRI diagnosis as part of the multi-layered approach for tumor classification was not recognized by the WHO expert panel. The compilation of the various layers of diagnostic findings into a multi-layered, genotype–phenotype classification scheme of FCD should

be addressed, however, by the treating physician (e.g., neurologist, epileptologist, neurosurgeon) and preferably with an interdisciplinary effort at a postsurgical patient management conference. The ILAE Task Force expects that the currently proposed integration will foster interdisciplinary cooperation among the many professional disciplines engaged in the clinical and therapeutic management of patients with FCD.

ACKNOWLEDGMENTS

DL was supported by 1R01NS117544-01 from the National Institute of Neurological Disorders and Stroke (NINDS).

AUTHORS' CONTRIBUTIONS

All authors participated in the discussions and unanimously agreed with the recommendations of the International League Against Epilepsy (ILAE) Task Force on FCD. The report was written by experts selected by the ILAE and was approved for publication by the ILAE. The opinions expressed by the authors, however, do not necessarily represent the policy or position of the ILAE. The special report was written by Imad Najm and Ingmar Blümcke. Fernando Cendes reviewed the first draft. The other co-authors contributed to the edits of various versions of the manuscript.


CONFLICT OF INTERESTS

Author JHL is a cofounder and chief technology officer (CTO) of SoVarGen, Inc., which seeks to develop new diagnostics and therapeutics for brain disorders. Author IN serves on an Advisory Board and Speakers Bureau of Eisai, Inc. The remaining authors have no conflicts of interest. We confirm that we have read the Journal's position on issues involved in ethical publication and affirm that this report is consistent with those guidelines.

ORCID

Imad Najm  <https://orcid.org/0000-0001-5192-2089>

Dennis Lal  <https://orcid.org/0000-0002-5173-9636>

Mario Alonso Vanegas  <https://orcid.org/0000-0002-7327-7014>

Fernando Cendes  <https://orcid.org/0000-0001-9336-9568>

Iscia Lopes-Cendes  <https://orcid.org/0000-0002-6221-6822>

Andre Palmiini  <https://orcid.org/0000-0002-4163-6924>
Christopher A. Walsh  <https://orcid.org/0000-0002-0156-2238>

Samuel Wiebe  <https://orcid.org/0000-0002-1061-9099>

Eleonora Aronica  <https://orcid.org/0000-0002-3542-3770>

Stéphanie Baulac  <https://orcid.org/0000-0001-6430-4693>

Katja Kobow  <https://orcid.org/0000-0002-0074-2480>

J. Helen Cross  <https://orcid.org/0000-0001-7345-4829>

Rita Garbelli  <https://orcid.org/0000-0002-6475-4974>

Hans Holthausen  <https://orcid.org/0000-0001-9221-0109>

Maria Thom  <https://orcid.org/0000-0001-7712-2629>

Assam El-Osta  <https://orcid.org/0000-0001-7968-7375>

Jeong Ho Lee  <https://orcid.org/0000-0002-2299-630X>

Hajime Miyata  <https://orcid.org/0000-0003-2551-5978>

Renzo Guerrini  <https://orcid.org/0000-0002-7272-7079>

Yue-Shan Piao  <https://orcid.org/0000-0001-6081-1129>

Dong Zhou  <https://orcid.org/0000-0001-7101-4125>

Ingmar Blümcke  <https://orcid.org/0000-0001-8676-0788>

REFERENCES

1. Crome L. Infantile cerebral gliosis with giant nerve cells. *J Neurol Neurosurg Psychiatry*. 1957;20(2):117–24.
2. Taylor DC, Falconer MA, Bruton CJ, Corsellis JA. Focal dysplasia of the cerebral cortex in epilepsy. *J Neurol Neurosurg Psychiatry*. 1971;34(4):369–87.
3. Palmini A, Gambardella A, Andermann F, Dubeau F, da Costa JC, Olivier A, et al. Intrinsic epileptogenicity of human dysplastic cortex as suggested by corticography and surgical results. *Ann Neurol*. 1995;37(4):476–87.
4. Blümcke I, Spreafico R, Haaker G, Coras R, Kobow K, Bien CG, et al. Histopathological findings in brain tissue obtained during epilepsy surgery. *N Engl J Med*. 2017;377(17):1648–56.
5. Lamberink HJ, Otte WM, Blümcke I, Braun KPJ. Seizure outcome and use of antiepileptic drugs after epilepsy surgery according to histopathological diagnosis: a retrospective multicentre cohort study. *Lancet Neurol*. 2020;19(9):748–57.
6. Bernasconi A, Cendes F, Theodore WH, Gill RS, Koepp MJ, Hogan RE, et al. Recommendations for the use of structural magnetic resonance imaging in the care of patients with epilepsy: a consensus report from the international league against epilepsy neuroimaging task force. *Epilepsia*. 2019;60(6):1054–68.
7. Tassi L, Colombo N, Garbelli R, Francione S, Lo Russo G, Mai R, et al. Focal cortical dysplasia: neuropathological subtypes, EEG, neuroimaging and surgical outcome. *Brain*. 2002;125(Pt 8):1719–32.
8. Palmini A, Najm I, Avanzini G, Babb T, Guerrini R, Foldvary-Schaefer N, et al. Terminology and classification of the cortical dysplasias. *Neurology*. 2004;62(6 Suppl 3):S2–8.
9. Chamberlain WA, Cohen ML, Gyure KA, Kleinschmidt-DeMasters BK, Perry A, Powell SZ, et al. Interobserver and intraobserver reproducibility in focal cortical dysplasia (malformations of cortical development). *Epilepsia*. 2009;50(12):2593–8.
10. Blümcke I, Thom M, Aronica E, Armstrong DD, Vinters HV, Palmini A, et al. The clinico-pathological spectrum of focal cortical Dysplasias: a consensus classification proposed by an ad hoc task force of the ILAE diagnostic Methods commission. *Epilepsia*. 2011;52(1):158–74.
11. Najm IM, Sarnat HB, Blümcke I. The international consensus classification of focal cortical dysplasia - a critical update 2018. *Neuropathol Appl Neurobiol*. 2018;44(1):18–31.

12. Blumcke I, Cendes F, Miyata H, Thom M, Aronica E, Najm I. Toward a refined genotype-phenotype classification scheme for the international consensus classification of focal cortical dysplasia. *Brain Pathol.* 2021;31(4):e12956.
13. Blumcke I, Coras R, Busch RM, Morita-Sherman M, Lal D, Prayson R, et al. Toward a better definition of focal cortical dysplasia: an iterative histopathological and genetic agreement trial. *Epilepsia.* 2021;62(6):1416–28.
14. Kobow K, Baulac S, von Deimling A, Lee JH. Molecular diagnostics in drug-resistant focal epilepsy define new disease entities. *Brain Pathol.* 2021;31(4):e12963.
15. Harvey AS, Mandelstam SA, Maixner WJ, Leventer RJ, Semmelroch M, MacGregor D, et al. The surgically remediable syndrome of epilepsy associated with bottom-of-sulcus dysplasia. *Neurology.* 2015;84(20):2021–8.
16. Ying Z, Wang I, Blumcke I, Bulacio J, Alexopoulos A, Jehi L, et al. A comprehensive clinico-pathological and genetic evaluation of bottom-of-sulcus focal cortical dysplasia in patients with difficult-to-localize focal epilepsy. *Epileptic Disord.* 2019;21(1):65–77.
17. Bonduelle T, Hartlieb T, Baldassari S, Sim NS, Kim SH, Kang HC, et al. Frequent SLC35A2 brain mosaicism in mild malformation of cortical development with oligodendroglial hyperplasia in epilepsy (MOGHE). *Acta Neuropathol Commun.* 2021;9(1):3.
18. Macdonald-Laurs E, Maixner WJ, Bailey CA, Barton SM, Mandelstam SA, Yuan-Mou Yang J, et al. One-stage, limited-resection epilepsy surgery for bottom-of-sulcus dysplasia. *Neurology.* 2021;97(2):e178–e90.
19. Lee WS, Stephenson SEM, Pope K, Gillies G, Maixner W, Macdonald-Laurs E, et al. Genetic characterization identifies bottom-of-sulcus dysplasia as an mTORopathy. *Neurology.* 2020;95(18):e2542–e51.
20. Schurr J, Coras R, Rossler K, Pieper T, Kudernatsch M, Holthausen H, et al. Mild malformation of cortical development with Oligodendroglial hyperplasia in frontal lobe epilepsy: a new Clinico-pathological entity. *Brain Pathol.* 2017;27(1):26–35.
21. Di Giacomo R, Deleo F, Garbelli R, Marucci G, Del Sole A, Dominese A, et al. Mild malformation of cortical development with oligodendroglial hyperplasia (MOGHE): neurophysiological fingerprints of a new pathological entity. *Clin Neurophysiol.* 2021;132(1):154–6.
22. Garganis K, Kokkinos V, Zountsas B, Dinopoulos A, Coras R, Blümcke I. Temporal lobe “plus” epilepsy associated with oligodendroglial hyperplasia (MOGHE). *Acta Neurol Scand.* 2019;140(4):296–300.
23. Hartlieb T, Winkler P, Coras R, Pieper T, Holthausen H, Blümcke I, et al. Age-related MR characteristics in mild malformation of cortical development with oligodendroglial hyperplasia and epilepsy (MOGHE). *Epilepsy Behav.* 2019;91:68–74.
24. Mendes Coelho VC, Morita-Sherman M, Yasuda CL, Alvim MMK, Amorim BJ, Tedeschi H, et al. Magnetic resonance imaging findings and clinical characteristics in mild malformation of cortical development with oligodendroglial hyperplasia and epilepsy in a predominantly adult cohort. *Epilepsia.* 2021;62(6):1429–41.
25. Gaballa A, Woermann FG, Cloppenborg T, Kalbhenn T, Blümcke I, Bien CG, et al. Clinical characteristics and postoperative seizure outcome in patients with mild malformation of cortical development and oligodendroglial hyperplasia. *Epilepsia.* 2021;62(12):2920–31.
26. Hirozawa D, Terada K, Matsuda K, Usui K, Usui N, Tottori T, et al. Characteristics of EEG seizure-onset patterns recorded from subdural electrodes over MRI-visible frontal focal cortical dysplasia type IIb lesions. *J Clin Neurophysiol.* 2017;34(5):427–33.
27. Lagarde S, Bonini F, McGonigal A, Chauvel P, Gavaret M, Scavarda D, et al. Seizure-onset patterns in focal cortical dysplasia and neurodevelopmental tumors: relationship with surgical prognosis and neuropathologic subtypes. *Epilepsia.* 2016;57(9):1426–35.
28. Lagarde S, Buzori S, Trebuchon A, Carron R, Scavarda D, Milh M, et al. The repertoire of seizure onset patterns in human focal epilepsies: determinants and prognostic values. *Epilepsia.* 2019;60(1):85–95.
29. Perucca P, Dubeau F, Gotman J. Intracranial electroencephalographic seizure-onset patterns: effect of underlying pathology. *Brain.* 2014;137(Pt 1):183–96.
30. Bouet R, Mauguière F, Daligault S, Isnard J, Guenot M, Bertrand O, et al. The relationship between morphological lesion, magnetic source imaging, and intracranial stereo-electroencephalography in focal cortical dysplasia. *Neuroimage Clin.* 2017;15:71–9.
31. Marusic P, Najm IM, Ying Z, Prayson R, Rona S, Nair D, et al. Focal cortical dysplasias in eloquent cortex: functional characteristics and correlation with MRI and histopathologic changes. *Epilepsia.* 2002;43(1):27–32.
32. Rampp S, Rossler K, Hamer H, Illek M, Buchfelder M, Doerfler A, et al. Dysmorphic neurons as cellular source for phase-amplitude coupling in focal cortical dysplasia type II. *Clin Neurophysiol.* 2021;132(3):782–92.
33. Wang I, Bernasconi A, Bernhardt B, Blumenfeld H, Cendes F, Chinvarun Y, et al. MRI essentials in epileptology: a review from the ILAE imaging taskforce. *Epileptic Disord.* 2020;22(4):421–37.
34. Wang I, Oh S, Blümcke I, Coras R, Krishnan B, Kim S, et al. Value of 7T MRI and post-processing in patients with nonlesional 3T MRI undergoing epilepsy presurgical evaluation. *Epilepsia.* 2020;61(11):2509–20.
35. De Ciantis A, Barba C, Tassi L, Cosottini M, Tosetti M, Costagli M, et al. 7T MRI in focal epilepsy with unrevealing conventional field strength imaging. *Epilepsia.* 2016;57(3):445–54.
36. Isler C, Kucukyuruk B, Ozkara C, Gunduz A, Is M, Tanriverdi T, et al. Comparison of clinical features and surgical outcome in focal cortical dysplasia type 1 and type 2. *Epilepsy Res.* 2017;136:130–6.
37. Kwon HE, Eom S, Kang HC, Lee JS, Kim SH, Kim DS, et al. Surgical treatment of pediatric focal cortical dysplasia: clinical spectrum and surgical outcome. *Neurology.* 2016;87(9):945–51.
38. Mata-Mbemba D, Iimura Y, Hazrati LN, Ochi A, Osubo H, Snead OC 3rd, et al. MRI, magnetoencephalography, and surgical outcome of Oligodendrocytosis versus focal cortical dysplasia type I. *AJNR Am J Neuroradiol.* 2018;39(12):2371–7.
39. Punia V, Bena J, Gonzalez-Martinez J, Bingaman W, Najm I, Stojic A, et al. Histopathologic substrate of drug-resistant epilepsy in older adults and the elderly undergoing surgery. *Epilepsia Open.* 2019;4(2):328–33.

40. Veersema TJ, Swampillai B, Ferrier CH, van Eijnden P, Gosselaar PH, van Rijen PC, et al. Long-term seizure outcome after epilepsy surgery in patients with mild malformation of cortical development and focal cortical dysplasia. *Epilepsia Open*. 2019;4(1):170–5.
41. Holthausen H, Coras R, Tang Y, Bai L, Wang I, Pieper T, et al. Multilobar unilateral hypoplasia with emphasis in the posterior quadrant and severe epilepsy in children with FCD ILAE type 1A. *Epilepsia*. 2021;PMCID:34741301–60.
42. Barkovich AJ, Kuzniecky RI, Bollen AW, Grant PE. Focal transmantle dysplasia: a specific malformation of cortical development. *Neurology*. 1997;49(4):1148–52.
43. Cendes F, Theodore WH, Brinkmann BH, Sulc V, Cascino GD. Neuroimaging of epilepsy. *Handb Clin Neurol*. 2016;136:985–1014.
44. Muhlechner A, Coras R, Kobow K, Feucht M, Czech T, Stefan H, et al. Neuropathologic measurements in focal cortical dysplasias: validation of the ILAE 2011 classification system and diagnostic implications for MRI. *Acta Neuropathol*. 2012;123(2):259–72.
45. Wang ZI, Alexopoulos AV, Jones SE, Najm IM, Ristic A, Wong C, et al. Linking MRI postprocessing with magnetic source imaging in MRI-negative epilepsy. *Ann Neurol*. 2014;75(5):759–70.
46. Tassi L, Garbelli R, Colombo N, Bramero M, Lo Russo G, Deleo F, et al. Type I focal cortical dysplasia: surgical outcome is related to histopathology. *Epileptic Disord*. 2010;12(3):181–91.
47. Lee JH, Huynh M, Silhavy JL, Kim S, Dixon-Salazar T, Heiberg A, et al. De novo somatic mutations in components of the PI3K-AKT3-mTOR pathway cause hemimegalencephaly. *Nat Genet*. 2012;44(8):941–5.
48. Poduri A, Evrony GD, Cai X, Elhosary PC, Beroukhi R, Lehtinen MK, et al. Somatic activation of AKT3 causes hemispheric developmental brain malformations. *Neuron*. 2012;74(1):41–8.
49. Riviere JB, Mirzaa GM, O'Roak BJ, Beddaoui M, Alcantara D, Conway RL, et al. De novo germline and postzygotic mutations in AKT3, PIK3R2 and PIK3CA cause a spectrum of related megalencephaly syndromes. *Nat Genet*. 2012;44(8):934–40.
50. D'Gama AM, Woodworth MB, Hossain AA, Bizzotto S, Hatem NE, LaCoursiere CM, et al. Somatic mutations activating the mTOR pathway in dorsal Telencephalic progenitors cause a continuum of cortical Dysplasias. *Cell reports*. 2017;21(13):3754–66.
51. Baldassari S, Ribierre T, Marsan E, Adle-Biasette H, Ferrand-Sorbets S, Bulteau C, et al. Dissecting the genetic basis of focal cortical dysplasia: a large cohort study. *Acta Neuropathol*. 2019;138(6):885–900.
52. D'Gama AM, Geng Y, Couto JA, Martin B, Boyle EA, LaCoursiere CM, et al. Mammalian target of rapamycin pathway mutations cause hemimegalencephaly and focal cortical dysplasia. *Ann Neurol*. 2015;77(4):720–5.
53. Jansen LA, Mirzaa GM, Ishak GE, O'Roak BJ, Hiatt JB, Roden WH, et al. PI3K/AKT pathway mutations cause a spectrum of brain malformations from megalencephaly to focal cortical dysplasia. *Brain*. 2015;138(Pt 6):1613–28.
54. Leventer RJ, Scerri T, Marsh AP, Pope K, Gillies G, Maixner W, et al. Hemispheric cortical dysplasia secondary to a mosaic somatic mutation in MTOR. *Neurology*. 2015;84(20):2029–32.
55. Lim JS, Gopalappa R, Kim SH, Ramakrishna S, Lee M, Kim WI, et al. Somatic mutations in TSC1 and TSC2 cause focal cortical dysplasia. *Am J Hum Genet*. 2017;100(3):454–72.
56. Lim JS, Kim WI, Kang HC, Kim SH, Park AH, Park EK, et al. Brain somatic mutations in MTOR cause focal cortical dysplasia type II leading to intractable epilepsy. *Nat Med*. 2015;21(4):395–400.
57. Mirzaa GM, Campbell CD, Solovieff N, Goold C, Jansen LA, Menon S, et al. Association of MTOR mutations with developmental brain disorders, including Megalencephaly, focal cortical dysplasia, and Pigmentary mosaicism. *JAMA Neurol*. 2016;73(7):836–45.
58. Moller RS, Weckhuysen S, Chipaux M, Marsan E, Taly V, Bebin EM, et al. Germline and somatic mutations in the MTOR gene in focal cortical dysplasia and epilepsy. *Neurology Genetics*. 2016;2(6):e118.
59. Nakashima M, Saitsu H, Takei N, Tohyama J, Kato M, Kitaoura H, et al. Somatic mutations in the MTOR gene cause focal cortical dysplasia type IIb. *Ann Neurol*. 2015;78(3):375–86.
60. Sim NS, Ko A, Kim WK, Kim SH, Kim JS, Shim KW, et al. Precise detection of low-level somatic mutation in resected epilepsy brain tissue. *Acta Neuropathol*. 2019;138(6):901–12.
61. Blumcke I, Budday S, Poduri A, Lal D, Kobow K, Baulac S. Neocortical development and epilepsy: insights from focal cortical dysplasia and brain tumours. *Lancet Neurol*. 2021;20(11):943–55.
62. Baulac S, Ishida S, Marsan E, Miquel C, Biraben A, Nguyen DK, et al. Familial focal epilepsy with focal cortical dysplasia due to DEPDC5 mutations. *Ann Neurol*. 2015;77(4):675–83.
63. Ribierre T, Deleuze C, Bacq A, Baldassari S, Marsan E, Chipaux M, et al. Second-hit mosaic mutation in mTORC1 repressor DEPDC5 causes focal cortical dysplasia-associated epilepsy. *J Clin Invest*. 2018;128(6):2452–8.
64. Lee WS, Baldassari S, Chipaux M, Adle-Biasette H, Stephenson SEM, Maixner W, et al. Gradient of brain mosaic RHEB variants causes a continuum of cortical dysplasia. *Ann Clin Transl Neurol*. 2021;8(2):485–90.
65. Pelorosso C, Watrin F, Conti V, Buhler E, Gelot A, Yang X, et al. Somatic double-hit in MTOR and RPS6 in hemimegalencephaly with intractable epilepsy. *Hum Mol Genet*. 2019;28(22):3755–65.
66. Khoshkhou S, Lal D, Walsh CA. Application of single cell genomics to focal epilepsies: a call to action. *Brain Pathol*. 2021;31(4):e12958.
67. Guerrini R, Cavallin M, Pippucci T, Rosati A, Bisulli F, Dimartino P, et al. Is focal cortical dysplasia/epilepsy caused by somatic MTOR mutations always a unilateral disorder? *Neurology Genetics*. 2021;7(1):e540.
68. Stevelink R, Sanders MW, Tuinman MP, Brilstra EH, Koeleman BP, Jansen FE, et al. Epilepsy surgery for patients with genetic refractory epilepsy: a systematic review. *Epileptic Disord*. 2018;20(2):99–115.
69. Ye Z, Chatterton Z, Pflueger J, Damiano JA, McQuillan L, Harvey AS, et al. Cerebrospinal fluid liquid biopsy for detecting somatic mosaicism in brain. *Brain Commun*. 2021;3(1):fcaa235.
70. Kim S, Baldassari S, Sim NS, Chipaux M, Dorfmueller G, Kim DS, et al. Detection of brain somatic mutations in cerebrospinal fluid from refractory epilepsy patients. *Ann Neurol*. 2021;89(6):1248–52.

71. Kobow K, Kaspi A, Hari Krishnan KN, Kiese K, Ziemann M, Khurana I, et al. Deep sequencing reveals increased DNA methylation in chronic rat epilepsy. *Acta Neuropathol.* 2013;126(5):741–56.
72. Kobow K, Ziemann M, Kaipananickal H, Khurana I, Muhlechner A, Feucht M, et al. Genomic DNA methylation distinguishes subtypes of human focal cortical dysplasia. *Epilepsia.* 2019;60(6):1091–103.
73. Debski KJ, Pitkanen A, Puhakka N, Bot AM, Khurana I, Hari Krishnan KN, et al. Etiology matters - genomic DNA methylation patterns in three rat models of acquired epilepsy. *Sci Rep.* 2016;6:25668.
74. Jabari S, Kobow K, Pieper T, Hartlieb T, Kudernatsch M, Polster T, et al. DNA methylation-based classification of malformations of cortical development in the human brain. *Acta Neuropathol.* 2022;143(1):93–104.
75. Kobow K, Jabari S, Pieper T, Kudernatsch M, Polster T, Woermann FG, et al. Mosaic trisomy of chromosome 1q in human brain tissue associates with unilateral polymicrogyria, very early-onset focal epilepsy, and severe developmental delay. *Acta Neuropathol.* 2020;140(6):881–91.
76. Wang DD, Piao YS, Blumcke I, Coras R, Zhou WJ, Gui QP, et al. A distinct clinicopathological variant of focal cortical dysplasia IIId characterized by loss of layer 4 in the occipital lobe in 12 children with remote hypoxic-ischemic injury. *Epilepsia.* 2017;58(10):1697–705.
77. Coras R, Holthausen H, Sarnat HB. Focal cortical dysplasia type 1. *Brain Pathol.* 2021;31(4):e12964.
78. Garbelli R, Milesi G, Medici V, Villani F, Didato G, Deleo F, et al. Blurring in patients with temporal lobe epilepsy: clinical, high-field imaging and ultrastructural study. *Brain.* 2012;135(Pt 8):2337–49.
79. Blumcke I, Aronica E, Becker A, Capper D, Coras R, Honavar M, et al. Low-grade epilepsy-associated neuroepithelial tumours - the 2016 WHO classification. *Nat Rev Neurol.* 2016;12(12):732–40.
80. Blumcke I, Aronica E, Miyata H, Sarnat HB, Thom M, Roessler K, et al. International recommendation for a comprehensive neuropathologic workup of epilepsy surgery brain tissue: a consensus task force report from the ILAE commission on diagnostic Methods. *Epilepsia.* 2016;57(3):348–58.
81. Blumcke I, Aronica E, Urbach H, Alexopoulos A, Gonzalez-Martinez JA. A neuropathology-based approach to epilepsy surgery in brain tumors and proposal for a new terminology use for long-term epilepsy-associated brain tumors. *Acta Neuropathol.* 2014;128(1):39–54.
82. Wang D, Blumcke I, Gui Q, Zhou W, Zuo H, Lin J, et al. Clinicopathological investigations of Rasmussen encephalitis suggest multifocal disease progression and associated focal cortical dysplasia. *Epileptic Disord.* 2013;15(1):32–43.
83. Wang DD, Blumcke I, Coras R, Zhou WJ, Lu DH, Gui QP, et al. Sturge-weber syndrome Is associated with cortical dysplasia ILAE type IIIc and excessive hypertrophic pyramidal neurons in brain resections for intractable epilepsy. *Brain Pathol.* 2015;25(3):248–55.
84. Miyata H, Kuwashige H, Hori T, Kubota Y, Pieper T, Coras R, et al. Variable histopathology features of neuronal dyslamination in the cerebral neocortex adjacent to epilepsy-associated vascular malformations suggest complex pathogenesis of focal cortical dysplasia ILAE type IIIc. *Brain Pathol.* 2022;e13052. Online ahead of print. <https://doi.org/10.1111/bpa.13052>
85. Marin-Padilla M, Parisi JE, Armstrong DL, Sargent SK, Kaplan JA. Shaken infant syndrome: developmental neuropathology, progressive cortical dysplasia, and epilepsy. *Acta Neuropathol.* 2002;103(4):321–32.
86. Sarnat HB, Hader W, Flores-Sarnat L, Bello-Espinosa L. Synaptic plexi of U-fibre layer beneath focal cortical dysplasias: role in epileptic networks. *Clin Neuropathol.* 2018;37(6):262–76, 276.
87. Winawer MR, Griffin NG, Samanamud J, Baugh EH, Rathakrishnan D, Ramalingam S, et al. Somatic SLC35A2 variants in the brain are associated with intractable neocortical epilepsy. *Ann Neurol.* 2018;83(6):1133–46.
88. Sim NS, Seo Y, Lim JS, Kim WK, Son H, Kim HD, et al. Brain somatic mutations in SLC35A2 cause intractable epilepsy with aberrant N-glycosylation. *Neurology Genetics.* 2018;4(6):e294.
89. Sarnat HB, Flores-Sarnat L. Neuroembryology and brain malformations: an overview. *Handb Clin Neurol.* 2013;111:117–28.
90. Rakic P. Defects of neuronal migration and the pathogenesis of cortical malformations. *Prog Brain Res.* 1988;73:15–37.
91. Cepeda C, Andre VM, Flores-Hernandez J, Nguyen OK, Wu N, Klapstein GJ, et al. Pediatric cortical dysplasia: correlations between neuroimaging, electrophysiology and location of cytomegaly neurons and balloon cells and glutamate/GABA synaptic circuits. *Dev Neurosci.* 2005;27(1):59–76.
92. Thom M, Eriksson S, Martinian L, Caboclo LO, McEvoy AW, Duncan JS, et al. Temporal lobe sclerosis associated with hippocampal sclerosis in temporal lobe epilepsy: neuropathological features. *J Neuropathol Exp Neurol.* 2009;68(8):928–38.
93. Slegers RJ, Blumcke I. Low-grade developmental and epilepsy associated brain tumors: a critical update 2020. *Acta Neuropathol Commun.* 2020;8(1):27.
94. Liu JY, Ellis M, Brooke-Ball H, de Tisi J, Eriksson SH, Brandner S, et al. High-throughput, automated quantification of white matter neurons in mild malformation of cortical development in epilepsy. *Acta Neuropathol Commun.* 2014;2:72.
95. Rubboli G, Plazzi G, Picard F, Nobili L, Hirsch E, Chelly J, et al. Mild malformations of cortical development in sleep-related hypermotor epilepsy due to KCNT1 mutations. *Ann Clin Transl Neurol.* 2019;6(2):386–91.
96. Skjei KL, Church EW, Harding BN, Santi M, Holland-Bouley KD, Clancy RR, et al. Clinical and histopathological outcomes in patients with SCN1A mutations undergoing surgery for epilepsy. *J Neurosurg Pediatr.* 2015;16(6):668–74.
97. Shimojima K, Okamoto N, Yamamoto T. A novel TUBB3 mutation in a sporadic patient with asymmetric cortical dysplasia. *Am J Med Genet A.* 2016;170A(4):1076–9.
98. Dalen Meurs-van der Schoor C, Van Weissenbruch M, Van Kempen M, Bugiani M, Aronica E, Ronner H, et al. Severe neonatal epileptic encephalopathy and KCNQ2 mutation: neuropathological substrate? *Front Pediatr.* 2014;2:136.
99. Emery JA, Roper SN, Rojiani AM. White matter neuronal heterotopia in temporal lobe epilepsy: a morphometric and immunohistochemical study. *J Neuropathol Exp Neurol.* 1997;56(12):1276–82.
100. Seetharam R, Nooraine J, Mhatre R, Ramachandran J, Iyer RB, Mahadevan A. Mild malformation of cortical development with oligodendroglial hyperplasia and epilepsy (MOGHE): a

- widespread disease with an apparently focal epilepsy. *Epileptic Disord.* 2021;23(2):407–11.
101. Verentzioti A, Blumcke I, Alexoudi A, Patrikelis P, Siatouni A, Korfias S, et al. Epileptic patient with mild malformation of cortical development with Oligodendroglial hyperplasia and epilepsy (MOGHE): a case report and review of the literature. *Case Rep Neurol Med.* 2019;2019:9130780.
 102. Blumcke I, Coras R, Wefers AK, Capper D, Aronica E, Becker A, et al. Review: challenges in the histopathological classification of ganglioglioma and DNT: microscopic agreement studies and a preliminary genotype-phenotype analysis. *Neuropathol Appl Neurobiol.* 2019;45(2):95–107.
 103. Coras R, de Boer OJ, Armstrong D, Becker A, Jacques TS, Miyata H, et al. Good interobserver and intraobserver agreement in the evaluation of the new ILAE classification of focal cortical dysplasias. *Epilepsia.* 2012;53(8):1341–8.
 104. Lariviere S, Federico P, Chinvarun Y, Jackson G, Morgan V, Rampp S, et al. ILAE neuroimaging task force highlight: harnessing optimized imaging protocols for drug-resistant childhood epilepsy. *Epileptic Disord.* 2021;23(5):675–81.
 105. Opheim G, van der Kolk A, Markenroth Bloch K, Colon AJ, Davis KA, Henry TR, et al. 7T epilepsy task force consensus recommendations on the use of 7T MRI in clinical practice. *Neurology.* 2021;96(7):327–41.
 106. Clavijo Prado CA, Federico P, Bernasconi A, Bernhardt B, Caciagli L, Concha L, et al. Imaging characteristics of temporopolar blurring in the context of hippocampal sclerosis. *Epileptic Disord.* 2022;24(1):1–8.

SUPPORTING INFORMATION

Additional supporting information may be found in the online version of the article at the publisher's website.

How to cite this article: Najm I, Lal D, Alonso Vanegas M, Cendes F, Lopes-Cendes I, Palmini A, The ILAE consensus classification of focal cortical dysplasia: An update proposed by an ad hoc task force of the ILAE diagnostic methods commission. *Epilepsia.* 2022;00:1–21. <https://doi.org/10.1111/epi.17301>